

Sinonasal Undifferentiated Carcinoma

Jill Remick,¹ MS4

Jolinta Lin,² MD

Pranshu Mohindra,² MD

1: George Washington University School of Medicine,
Washington

2: Department of Radiation Oncology, University of Maryland,
Baltimore

CASE 1

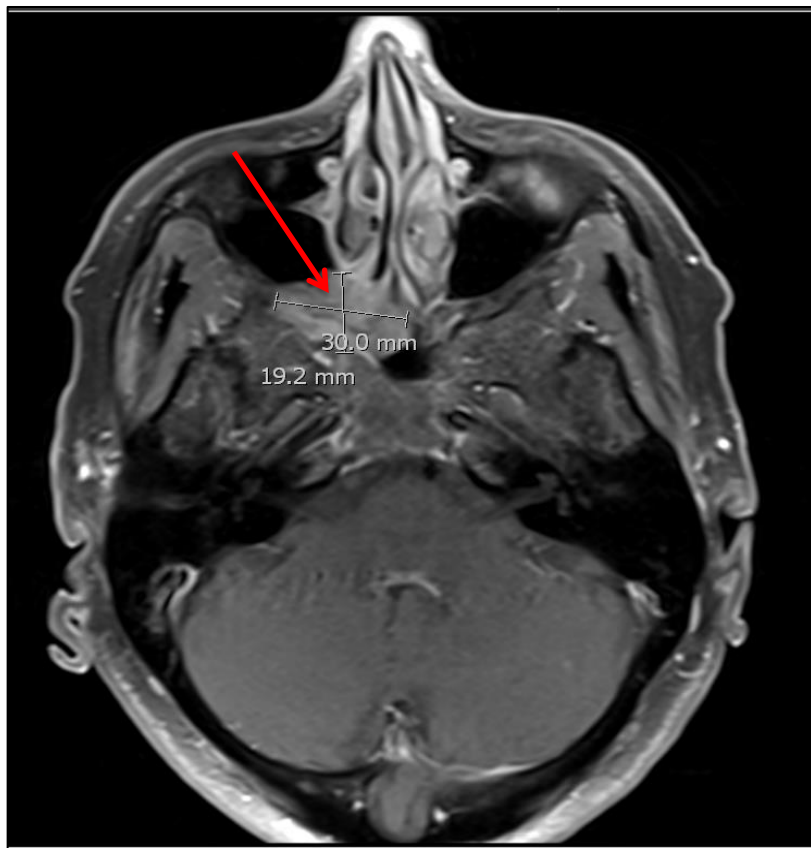
HPI:

- 71yo F with history of GERD and HTN
- Presented with nausea and dizziness after bumping her head on windowsill
- Denied visual changes or any other neurological symptoms

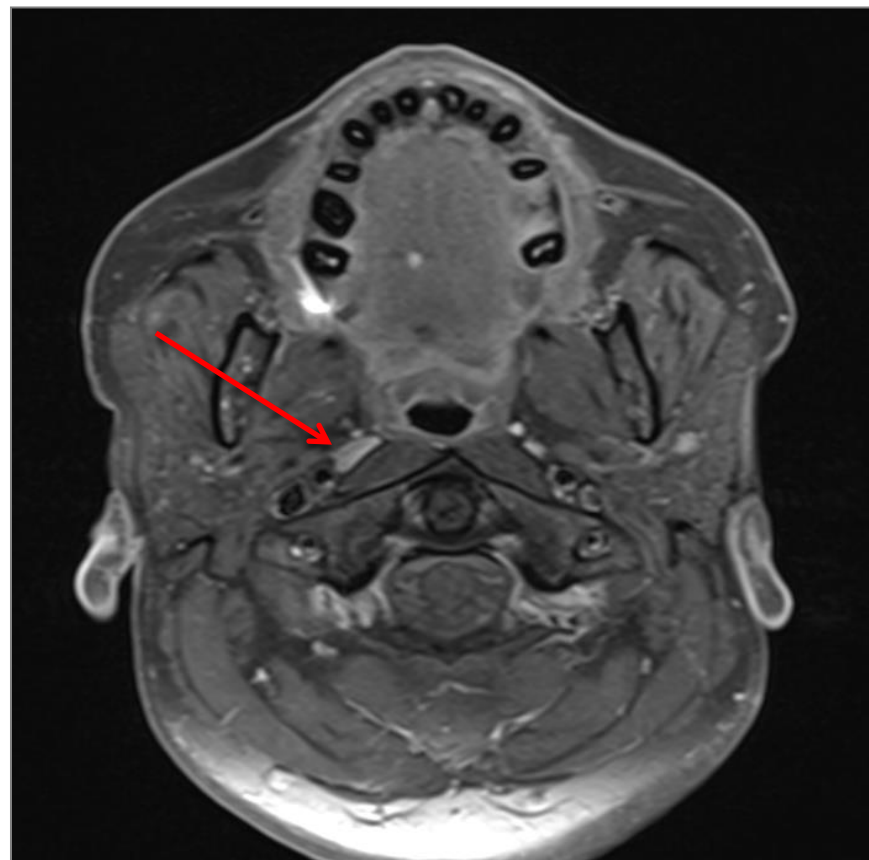
Pertinent exam findings:

- General- appears in no distress, ECOG 0
- HEENT– slight ptosis of right eye, pupils equal and reactive to light, no facial numbness, other CN II-XII grossly intact, vision intact, negative anterior nasal exam, OC/Ophx clear, no palpable LAD
- Neuro: sensation intact throughout, 5/5 strength all extremities, gait/balance intact
- Remainder of exam was normal
- Nasal Endoscopy Under Anesthesia: visible tumor erosion of the posterior wall of the right maxillary sinus. There was also tumor in the ethmoid cells exposing anterior and posterior ethmoid cells, sphenoids, and skull base. There was no orbital fat involvement from the nasal cavity seen.

IMAGING



T1 post gad – nasal mass



T1 post gad – RPLN

Description: MRI shows a solid enhancing lesion centered in the posterior superior right nasal canal with extension into the pterygoid palatine fossa measuring 3.0cm in greatest dimension. There is bony invasion of the maxillary sinus and sphenoid. There is no intracranial or orbital involvement. There is also a borderline enlarged right retropharyngeal lymph node (RPLN).

Other imaging: PET-CT – no evidence of nodal or distant disease.

CASE 2

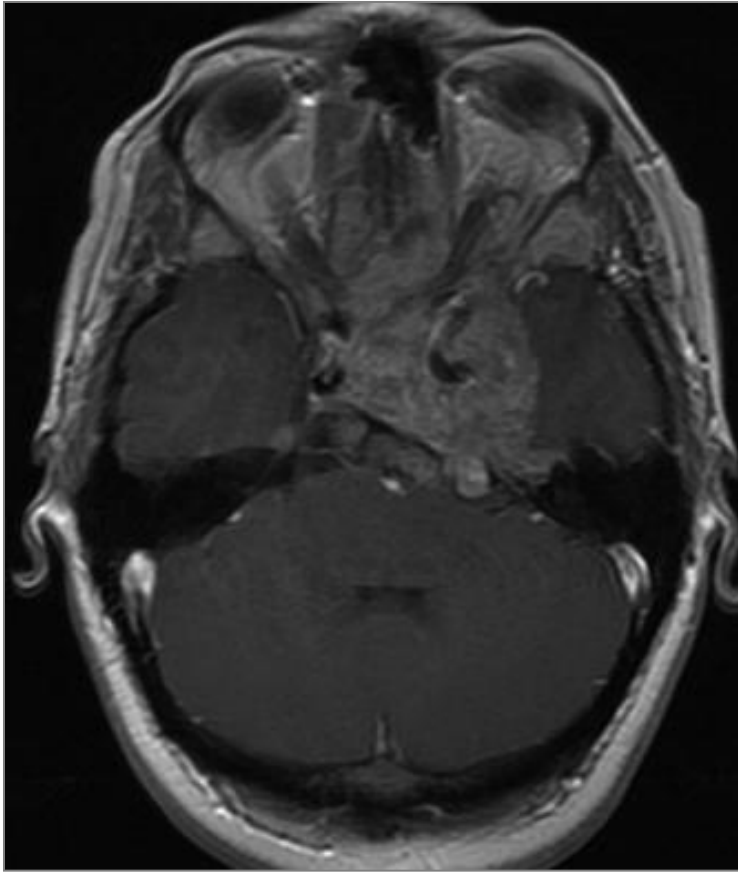
HPI:

- 27yo F with no significant medical history, presents with worsening headaches over the last several days-wks, first started about 6-8 months ago
- Sudden, severe respiratory distress at an outside institution, requiring intubation

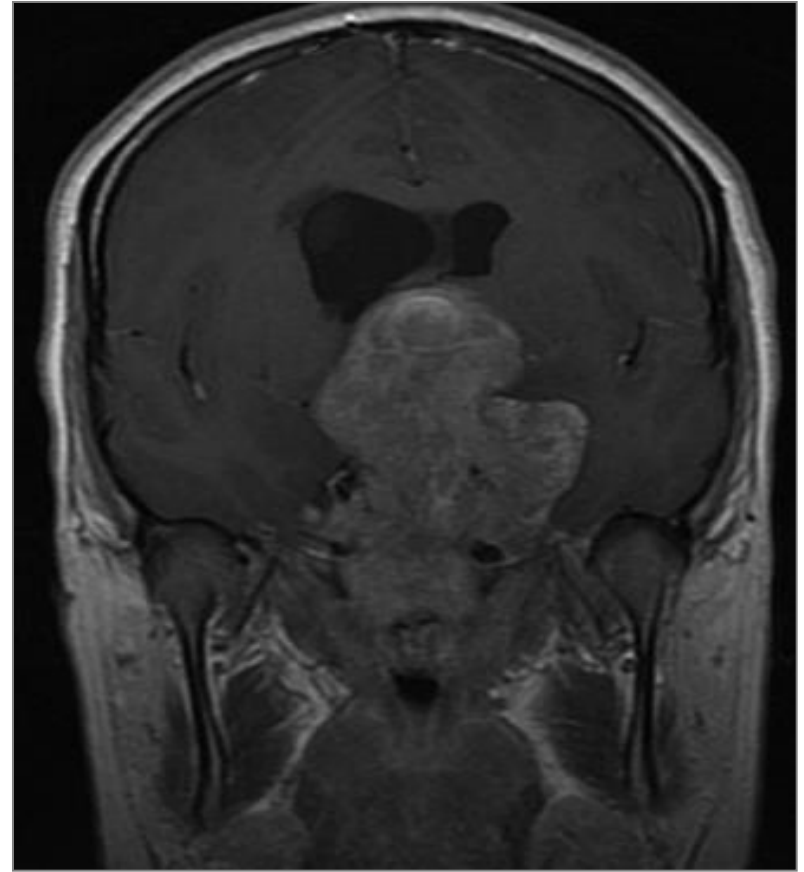
Pertinent exam findings:

- General: appears stated age, intubated, ECOG 4
- HEENT: left pupil was 5mm and reactive to 3mm sluggishly, right pupil was 3mm and reactive to 2mm
- Neuro: ptosis on left, left VI cranial n. palsy
- Extremities: Patient localizes to pain and moves all 4 extremities
- Remainder of exam was normal
- Nasal Endoscopy Under Anesthesia: left anterior nasal cavity normal, a large hyperemic mass was visualized in posterior left nasal cavity that extended into posterior nasopharynx.

IMAGING



T1 post gad- Axial



T1 post gad- Coronal

Description: MRI shows a heterogeneously enhancing mass, 8 cm in greatest dimension, located at the base of the skull with bony invasion of the clivus, sella and sphenoid sinus as well as significant intracranial extension. The mass also extends into the nasal cavity, nasopharynx and orbit.

Other imaging: PET-CT – no evidence of nodal or distant disease.

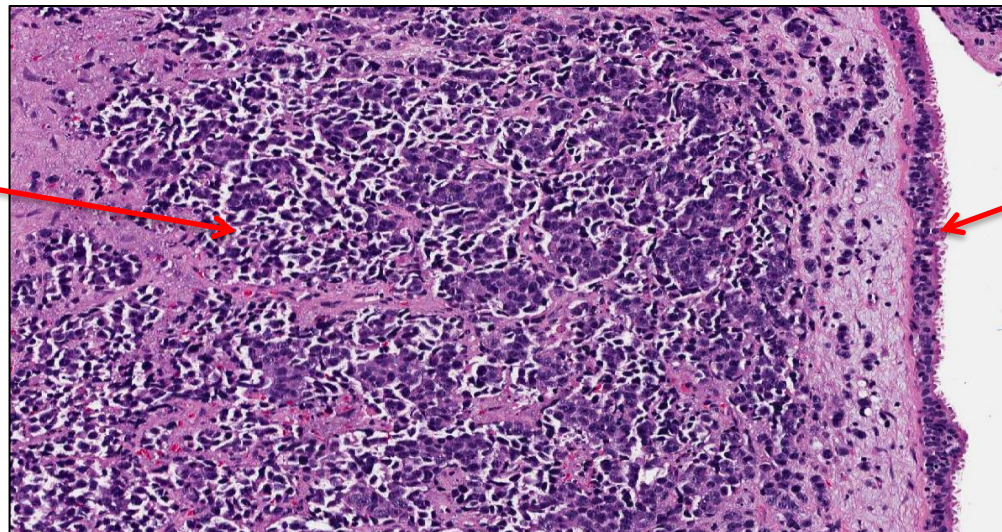
WORK-UP FOR PARANASAL SINUS MASS

- Detailed H&P with a complete HEENT/Neurological examination
- Baseline ophthalmology consult to document visual function including visual field testing
- Fiberoptic nasopharyngoscopy
- Biopsy (trans-nasal or endoscopic-guided)
- CT or MRI Head-Neck with IV contrast
 - To assess primary tumor and nodal disease
 - MRI if base-skull/orbital/intracranial involvement to delineate primary tumor extent for operative assessment and/or radiation planning
- Consider PET-CT scan for Stage III or IV
 - assess regional and distant staging
- Chest imaging as clinically indicated
- Dental exam if clinically indicated

PATHOLOGY FROM BIOPSY (case 1 and 2)

- Medium-sized, cohesive cells
- Arranged in nests and trabeculae
- High mitotic rate, high nuclear:cytoplasm ratio, necrosis, prominent vascular invasion
- Reactive for cytokeratin, epithelial membrane antigen and neuron-specific enolase
- Final diagnosis: Sinonasal Undifferentiated Carcinoma (SNUC)

Pleomorphic tumor cells



Normal respiratory epithelium

H&E high power

ASSOCIATION OF RESIDENTS IN RADIATION ONCOLOGY



DDX: High-Grade, Anaplastic Neoplasms of the Sinonasal Tract

- Sinonasal Undifferentiated Carcinoma (SNUC)
- Olfactory Neuroblastoma or Esthesioneuroblastoma (ENB)
- Neuroendocrine Carcinoma
- Small Cell Carcinoma
- Lymphoma
- Mucosal Melanoma
- Rhabdomyosarcoma
- Lymphoepithelioma (Nasopharyngeal Undifferentiated Carcinoma)

* Teaching point: Diagnosis of SNUC can be difficult because it may resemble other neoplasms clinically and radiographically. The diagnosis can usually be made with light microscopy alone if adequate tissue samples are obtained.

SNUC – INTRODUCTION

- **Very rare tumor of the paranasal sinus (<3% of head and neck cancers) – classified as undifferentiated neuroendocrine tumor**
- **Originates from nasal cavity/paranasal sinus epithelium**
- **Disease is typically locally advanced at presentation – often into adjacent sinuses or beyond – can involve orbit/skull/brain**
- **10-30% present with clinically positive lymph nodes**
- **Distant metastasis at diagnosis is very unusual; however, distant mets can occur with recurrent disease, most often to lung and bone**
- **Local and distant recurrence both may be important causes of treatment failure**

STAGING NASAL CAVITY/ETHMOID SINUS

(AJCC 7th ED., 2010)

T stage

T1: restricted to 1 subsite +/- bone invasion

T2: involves 2 subsites in single region or extends to involve adjacent region +/- bone invasion

T3: involves medial wall or floor of orbit/maxillary sinus/palate/cribriform plate

T4a: invades any of following – anterior orbital contents, skin, minimal extension into anterior cranial fossa, pterygoid plates, sphenoid or frontal sinus

T4b: invades orbital apex, dura, brain, middle cranial fossa, cranial nerves (other than V₂), nasopharynx or clivus

N stage

N1: single ipsilateral lymph node involvement \leq 3cm

N2: none greater than 6cm in greatest dimension

N2a: single ipsilateral $>$ 3cm but $<$ 6cm

N2b: multiple ipsilateral

N2c: bilateral or contralateral

N3: lymph node $>$ 6cm in greatest dimension

Overall Stage

Stage I: T1 N0 M0

Stage II: T2 N0 M0

Stage III: T1-2 N1 M0, T3 N0-1 M0

Stage IVA: T4a N0-2 M0, T1-3 N2 M0

Stage IVB: T4b Any N M0, Any T N3 M0

Stage IVC: Any T, Any N, M1

ALTERNATIVE STAGING: KADISH

| Stage | Characteristics |
|-------|--|
| A | Confined to nasal cavity |
| B | Confined to nasal cavity and paranasal sinus |
| C | Beyond nasal cavity and paranasal sinus |

* Teaching Point: Kadish staging was originally described for esthesioneuroblastoma (ENB), but has shown to correlate with outcomes in SNUC

SNUC – GENERAL MANAGEMENT

- **Trimodality therapy results in the best outcomes**
- **Surgery, when feasible, may improve local control (Reiersen et al)**
- **Resectable or marginally resectable:**
 - **Primary surgery followed by adjuvant chemo-radiotherapy may be preferable**
 - **May consider induction chemotherapy (Cyclophosphamide/Doxorubicin/Vincristine) followed by re-assessment for surgery (Musy et al)**
- **Unresectable:**
 - **Concurrent chemoradiation**
 - **Induction chemotherapy followed by concurrent chemoradiation (Rischen et al)**
- **Optimal sequence of modalities and choice of chemotherapy regimen is still unclear**

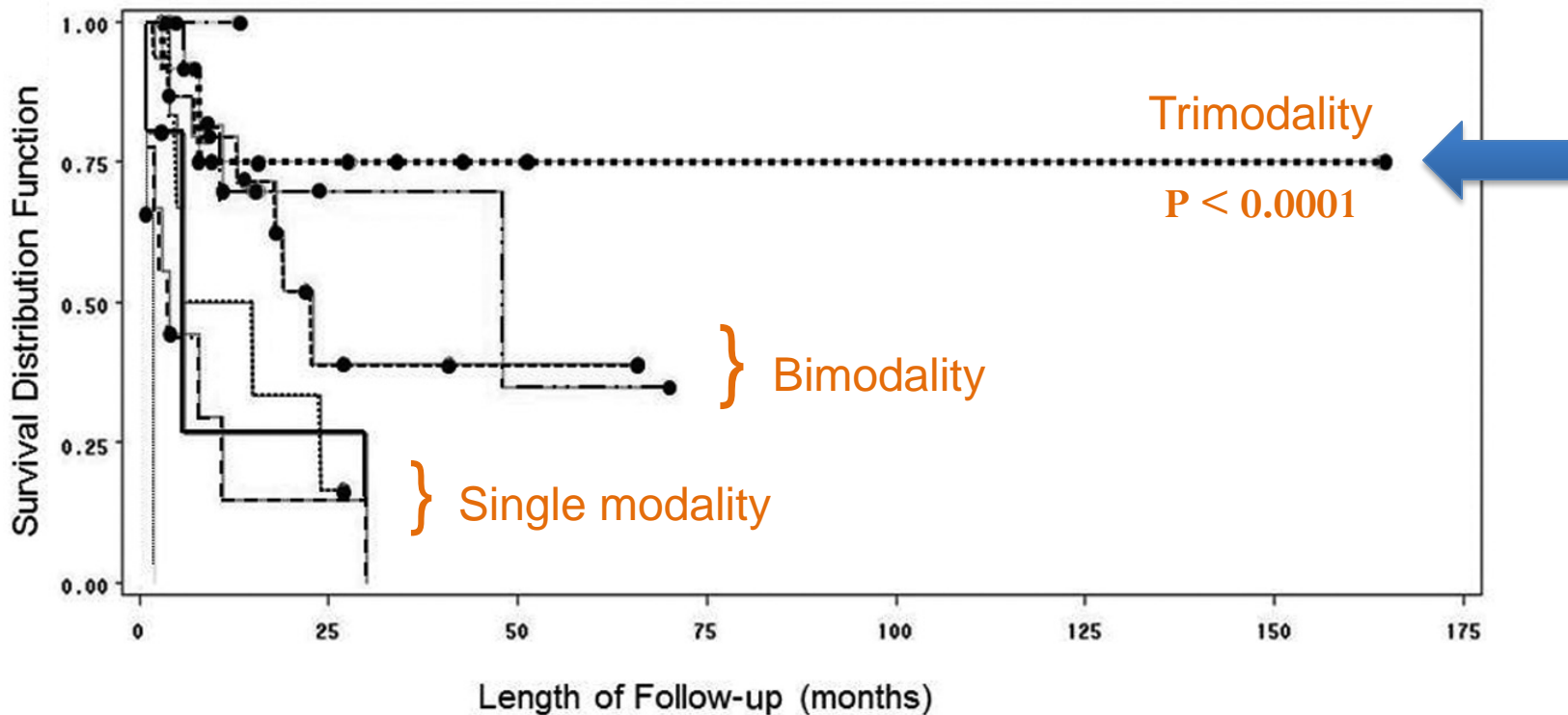
GENERAL OUTCOMES

| Outcome | Median | Range |
|---|--------|--------|
| Local Control (2-year) | 60% | 43-83% |
| Regional Control (5-year) | 84% | 78-90% |
| Distant Metastasis-Free Survival (5-year) | 75% | 35-90% |
| Overall Survival: | | |
| 2-year | 63% | 45-74% |
| 5-year | 43% | 20-74% |

- This table compiles the data of 10 retrospective case studies.⁴⁻¹³
- This demonstrates the wide range of outcomes that have been observed.
- Generally, local and distant recurrence are more common causes of distal failure in this disease.

TRIMODALITY THERAPY IMPROVES CHANCE OF SURVIVAL

SNUC Stage C Survival and Treatment Regimen



Reiersen DA, Pahilan ME, Devaiah AK. Meta-analysis of treatment outcomes for sinonasal undifferentiated carcinoma. *Otolaryngology Head and Neck Surg.* 2012;147;7-14.

BACK TO THE CASES

Case 1

- Deemed unresectable due to involvement of the base skull
- Initiated on concurrent chemo-radiotherapy with curative intent

Case 2

- Due to significant intracranial extension, upfront radiotherapy to definitive doses was not feasible
- In the setting of bulky disease and limitations of normal tissue constraints, she was initiated on induction chemotherapy to be followed by re-assessment for sequential radiotherapy

RADIATION PLANNING

- **Simulation:**
 - Supine, head neutral, shoulder traction, thermoplastic immobilization mold
 - Planning CT with IV contrast
- **Contouring:**
 - Diagnostic MRI co-registered with planning CT for contouring
- **Radiation doses from literature:**

| | Neoadjuvant (Musy et al) | Post Op-RT (Tanzler et al) | Definitive (Tanzler et al) |
|-------------|------------------------------------|--------------------------------------|--------------------------------------|
| Median Dose | 50 Gy | 64.8 | 70.8Gy BD/QD |
| Range | 50-54 Gy | 62.4-74.4 Gy | 70-74.8 Gy |

* Teaching Point: Standard 1.8-2 Gy, once daily fractionation is most commonly used. In situations with close proximity to the neural structures, hyperfractionation with twice daily fractions can be used to reduce the risk of late toxicity or in this case, blindness.

RADIATION PLANNING: CASE 1

- **Target Volumes:**
 - Sequential phase IMRT plan was developed*
 - GTV = nasal mass + right retropharyngeal LN
 - CTV1 = (GTV + 1 - 1.5 cm margin, modified at natural barriers) + ENI (Bilateral RP + level II-IV**)
 - Phase I (Initial Volume): 48.4 Gy in 44 fx, @ 1.1Gy BID***

* Sequential phase plan per institutional practice. May also be performed with differential dose-per-fraction, dose-painting IMRT techniques.

** While in nasopharyngeal carcinoma level V is considered at high risk site of involvement, nodal volumes of SNUC are based on the location and extent of the disease. In case 1, the tumor originated in the posterior nasal cavity, with only a borderline RPLN noted on MRI. Hence, the level V lymph nodes were excluded from the CTV.

*** Due to close proximity to neural structures, hyperfractionation with twice daily fractions were employed to reduce the risk of late toxicity. For sites not in proximity to critical structures, standard 1.8-2 Gy once daily fractionation is typically used.

RADIATION PLANNING: CASE 1

- **CTV2 = GTV + 0.5 – 1 cm margin, modified at natural barriers**
- **Phase II (Small field boost): 24.2Gy in 22 fx, @ 1.1Gy BID**
- **PTV = CTV + 3mm (institutional practice)**
- **Standard Head-Neck organs-at-risk (OAR) delineate**
- **Total PTV Dose: 72.6 Gy in 66 fx @ 1.1 Gy BID**

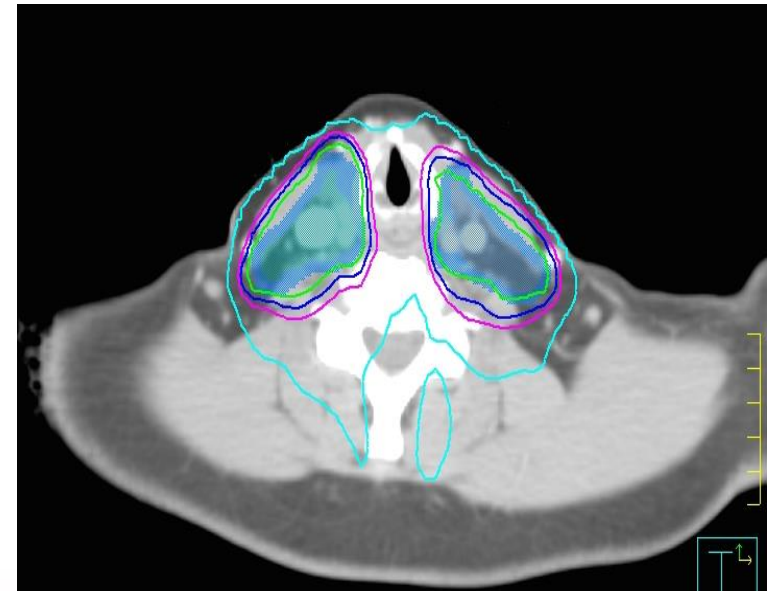
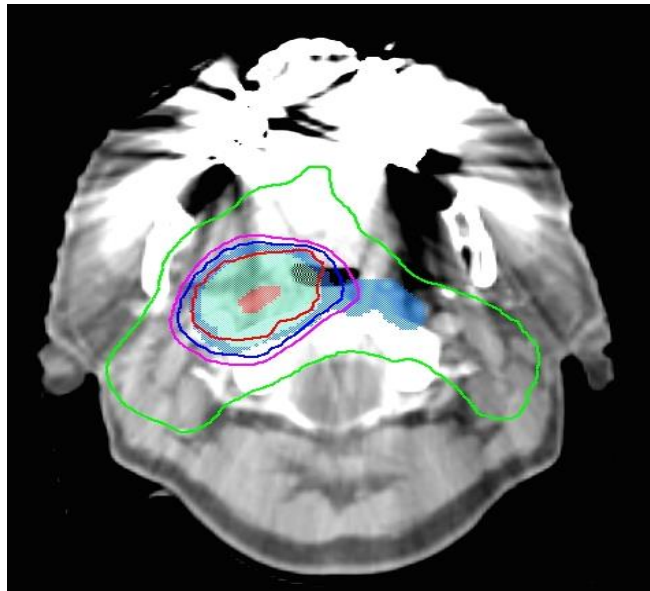
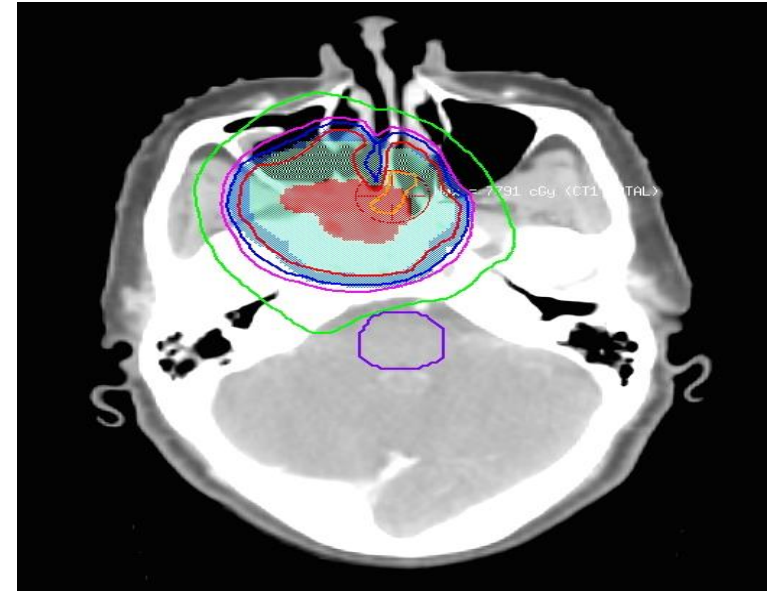
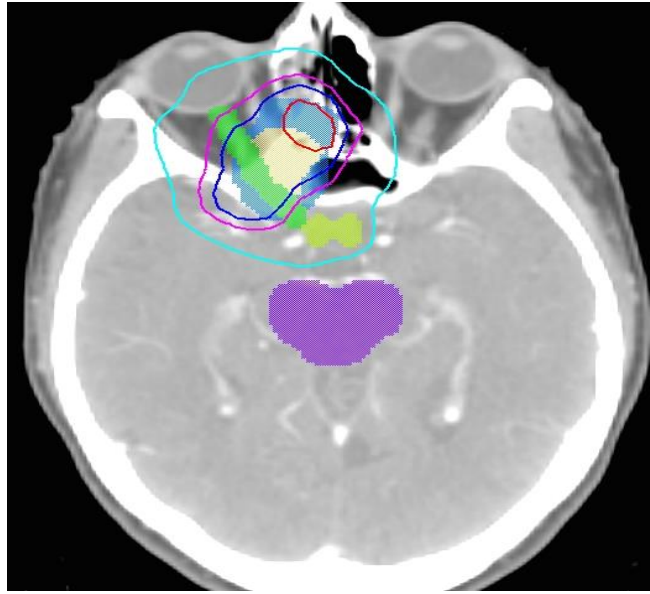
IMRT PLAN – CTV1

Volumes:

- GTV – Red
- CTV1 – Yellow
- PTV1 – Blue

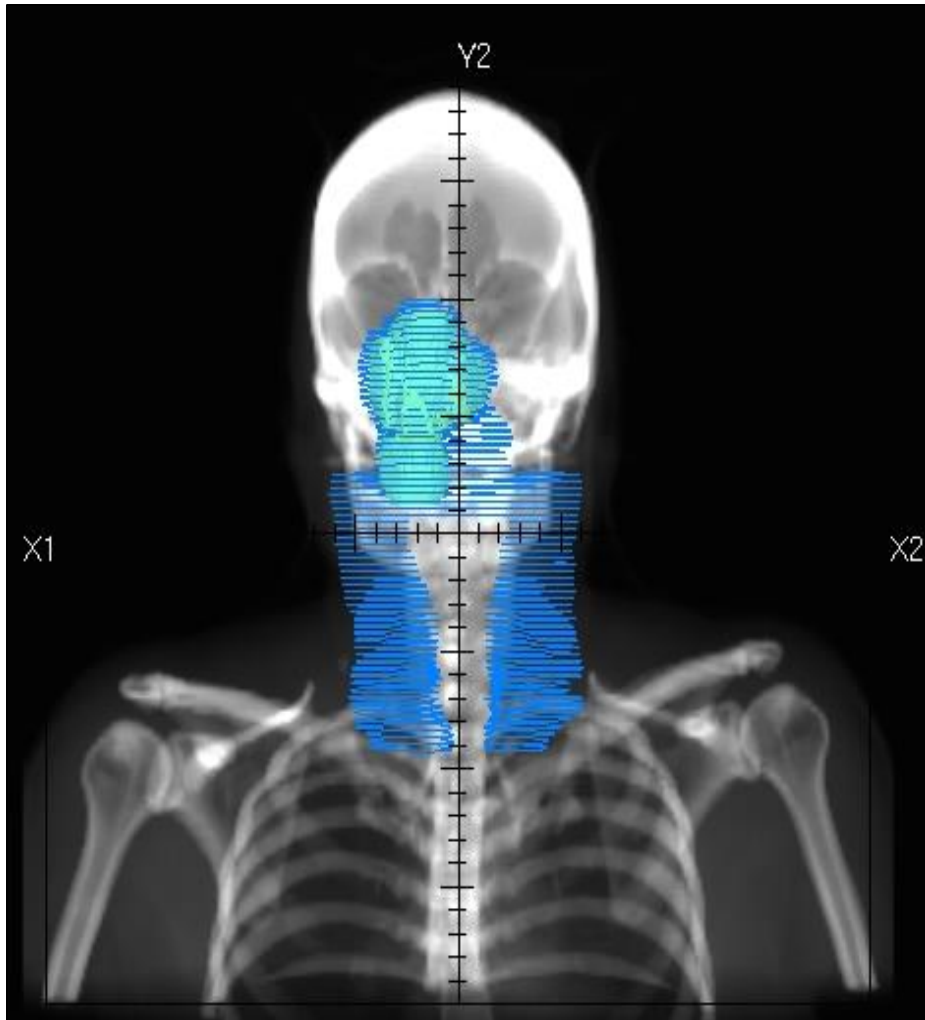
Normal structures (in colorwash)

- Brainstem – Purple
- Optic nerve – Green
- Chiasm – yellow-green



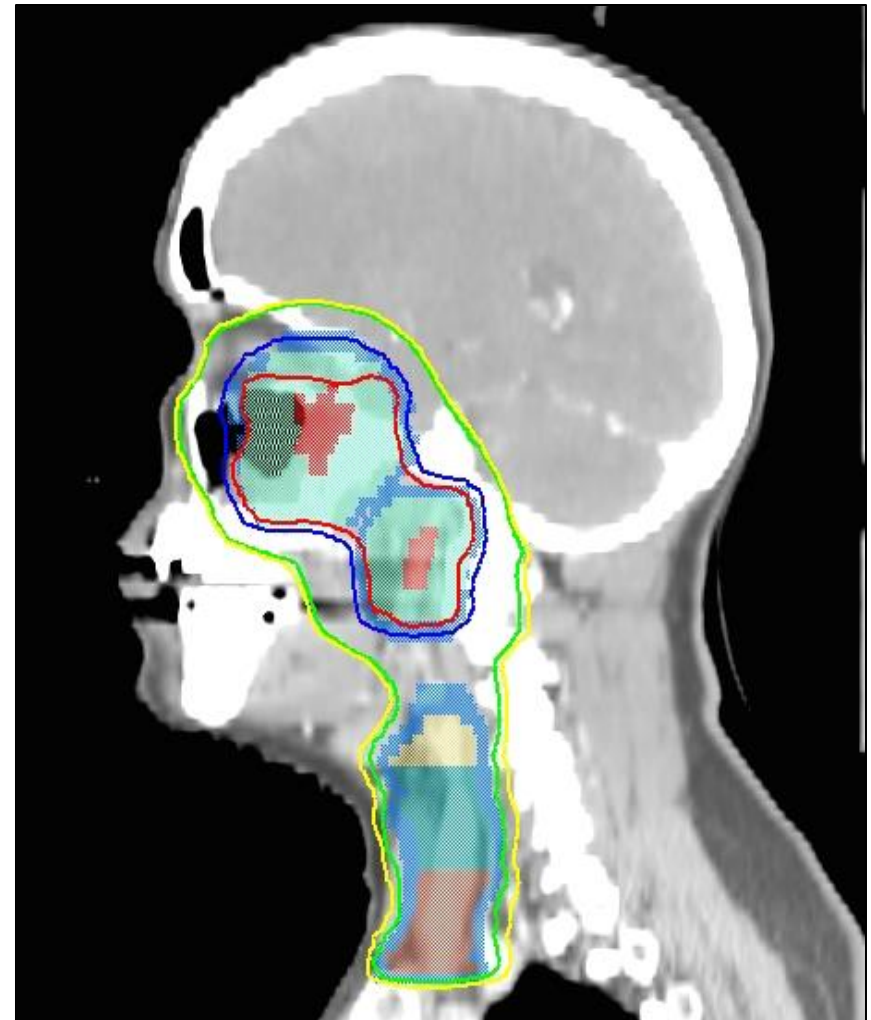
| Absolute |
|------------|
| 4840.0 cGy |
| 7623.0 cGy |
| 7260.0 cGy |
| 6897.0 cGy |
| 6534.0 cGy |

AP FIELD-DRR



CTV1 – Yellow PTV1 – Blue

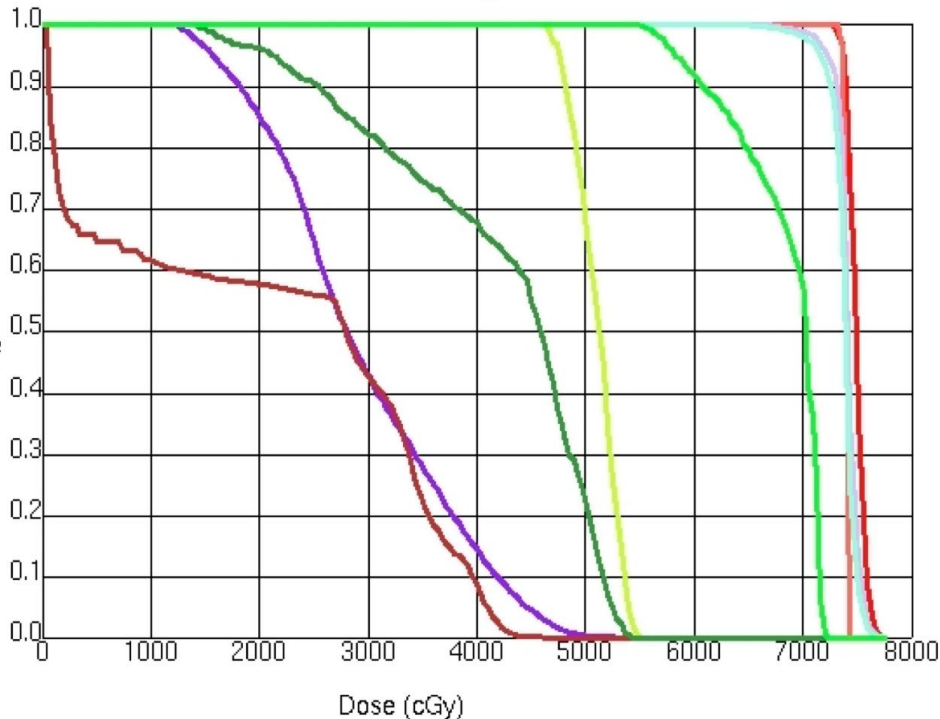
LATERAL VIEW



Patient H&P, treatment planning details: Courtesy of Dr. William Regine, Professor and Chair, Dept. of Radiation Oncology, University of Maryland, Baltimore

DVH

Dose Volume Histogram



- GTV (primary) – red
- GTV (node) – orange
- CTV2 – lavender
- PTV2 – sky blue
- Bright green – right optic nerve
- Chiasm – yellow-green
- Forest green – left optic nerve
- Brainstem – purple
- Spinal Cord – maroon

| OAR | Dose Constraint (Gy) | Actual DVH Value (Gy) |
|-------------|--------------------------|------------------------|
| Brainstem | Max < 54 | 52.6 |
| Cord | V50 < 0.1% V48 < 0.3% | V50: 0.0% V48: 0.0% |
| Chiasm | Max < 55 | 54.9 |
| Optic Nerve | Max < 55 | *Right: 72.2 |
| | | Left: 54.3 |
| Retina | Max < 45 | *Right: 69.6 |
| | | Left: 28.9 |
| Cochlea | Mean ≤ 35 | *Right: 47.3 |
| | | Left: 33.3 |
| Lens | Max < 10 | *Right: 45.8 |
| | | Left: 10.7 |

* Teaching Point: OARs on the left side were prioritized in order to preserve contralateral nerve function.

ON TREATMENT ISSUES/MANAGEMENT

- Mucositis – topical numbing mouthwash, oral hygiene, opioid based analgesics, baking soda and salt solution
- Dry mouth – lozenges
- Dry eyes – eye drops
- Maintain diet and hydration, PEG tube, IV fluid support PRN
- Skin care – non-alcoholic, water-based creams/ lotions
- Monitor labs
- Case 1 needed a treatment break due to significant nausea/vomiting/failure to thrive, grade 3 weight loss requiring peg tube placement. Changes to her treatment included a switch from cisplatin to weekly carboplatin and a re-planning scan to account for >10% weight-loss. The remaining treatment course was given at a higher dose-per fraction, 1.5 Gy bid.

CASE-SPECIFIC POINTS

- **These cases highlight the challenges in managing rare diseases in which there is little data available**
- **SNUC is rapidly progressive and presents with locally advanced disease**
- **Lymph node involvement at presentation is rare but associated with worse prognosis**
- **Elective nodal dissection/ irradiation recommended**
- **Studies have advocated for trimodality therapy with surgery having the most significant impact on overall survival**

REFERENCES

1. Reiersen DA, Pahilan ME, Devaiah AK. Meta-analysis of treatment outcomes for sinonasal undifferentiated carcinoma. *Otolaryngology Head and Neck Surg.* 2012;147:7-14.
2. Frierson HF Jr, Ross GW, Stewart FM, et al. Unusual sinonasal small-cell neoplasm following radiotherapy for bilateral retinoblastoma. *Am J SurgPathol.* 1989;13:947-54.
3. Rischin D, Porseddu S, Peters L, et al. Promising results with chemoradiation in patients with sinonasal undifferentiated carcinoma. *Head Neck.* 2004;26:435-441.
4. Al-Mamgani A, van Rooij P, Mehilal R, et al. Combined-modality treatment improved outcome in sinonasal undifferentiated carcinoma: single-institutional experience of 21 patients and review of the literature. *Eur Arch Otorhinolaryngol* 2013;270:293-9.
5. Chen AM, Daly ME, El Sayed I et al. Patterns of failure after combined-modality approaches incorporating radiotherapy for sinonasal undifferentiated carcinoma of the head and neck. *Int J RadiatOncolBiol Phys.* 2008;70:338-343.
6. Musy PY, Reibel JF, Levine PA. Sinonasal undifferentiated carcinoma: the search for a better outcome. *Laryngoscope.* 2002; 112:1450-1455.
7. Mourad WF, Hauerstock, D, Shourbaji RA, et al. Trimodality management of sinonasal undifferentiated carcinoma and review of the literature. *Am J ClinOncol* 2012.
8. Christopherson K, Werning JW, Malyapa RS, et al. Radiotherapy for sinonasal undifferentiated carcinoma. 2013. *Am J Orolaryngology.* 2014; 35:141-146.
9. Lin EM, Sparano A, Spalding A et al. Sinonasal undifferentiated carcinoma: a 13-year experience at a single institution. *Skull Base.* 2010; 20:61-67.
10. Rosenthal DI, Barker JL, El-Naggar AK et al. Sinonasal malignancies with neuroendocrine differentiation: patterns of failure according to histologic phenotype. *Cancer.* 2004;101:2567-2573.
11. Tanzler ED, Morris CG, Orlando CA, Werning JW, Mendenhall WM. Management of sinonasal undifferentiated carcinoma. *Head Neck.* 2008;30:595-599.
12. Miyamoto C, Gleich L, Biddinger P, Gluckman JL. Esthesioneuroblastoma and sinonasal undifferentiated carcinoma: impact of histological grading and clinical staging on survival and prognosis. *Laryngoscope.* 2000; 110:1262-1265
13. Rischin D, Porseddu S, Peters L, et al. Promising results with chemoradiation in patients with sinonasal undifferentiated carcinoma. *Head Neck.* 2004;26:435-441.

Please provide feedback regarding this case or other ARROcases to arrocase@gmail.com