

ARROcase

Anal Canal Carcinoma

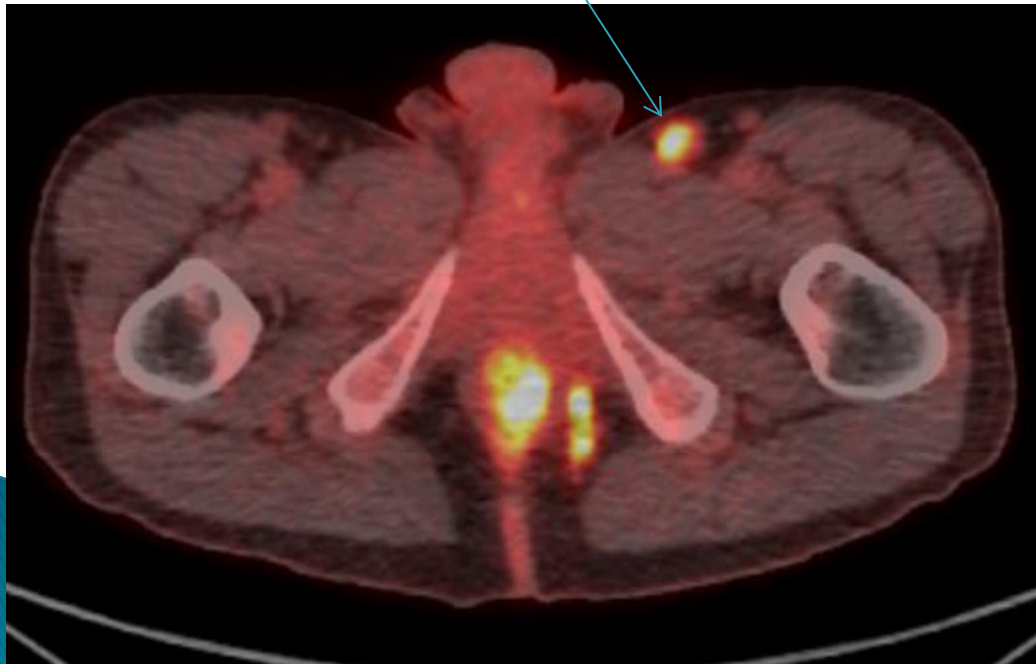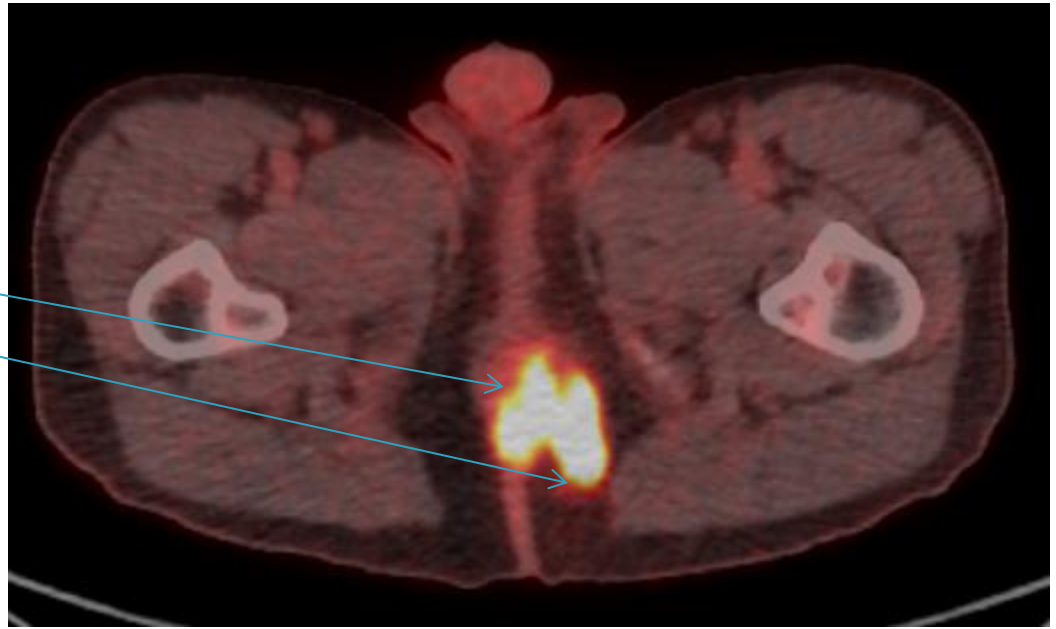
Shripal Bhavsar, MD, MBA
SUNY Upstate Medical University
Syracuse, NY

Case Presentation


- 45 year old man with HIV, CD4 70
 - CC: Anal pain x 6 months, thought they were hemorrhoids
 - PE: Palpable 2cm rectal mass extending to anorectal ring with fluctuant left-sided gluteal mass and 2 cm palpable L inguinal LN
 - Biopsy reveals SqCCa and abscess drained.
 - PET/CT - anal canal mass with associated fistula into left ischioanal fossa, SUV max 12.4, left inguinal nodes SUV 7.2
- ▶ Stage T2N2, IIIB

PET/CT


- ▶ Primary
- ▶ Fistula/Abscess
- ▶ Palpable Node



Epidemiology

- ▶ Anal Cancer accounts for ~ 2.0% of all new cancers diagnosed per year
 - ▶ 6,230 men and women (2,250 men and 3,980 women) will be diagnosed with and 780 men and women will die of cancer of the anus, anal canal, and anorectum in 2012
 - ▶ More common in urban populations
 - ▶ Higher risk in men/women with AIDS, increases risk (RR is from 30 to 60), particularly in CD4 <200
 - ▶ High-grade intraepithelial lesions are precursors and HPV may be causative
- 

Risk Factors

- HPV 16, 18, 33, 34, 35
 - AIDS Diagnosis (Immunosuppression)
 - Smoking
 - Multiple sexual partners, Receptive Anal Intercourse, history of prior STI
 - History of vulvar, vaginal or cervical cancer
- 

Presentation

- ▶ Symptoms
 - Rectal Bleeding (most common)
 - Change in bowel habits (constipation or urgency)
 - Palpable mass
 - Pruritus
- ▶ Often prolonged time to presentation from symptom onset
 - Nearly 33% of patients may prolong telling physician for 6 months⁵
 - Non-specific symptomatology
- ▶ Symptoms lend to earlier diagnosis
 - 73% diagnosed in Stage 0 to II and only 4% in Stage IV⁴

Workup and Staging (NCCN)

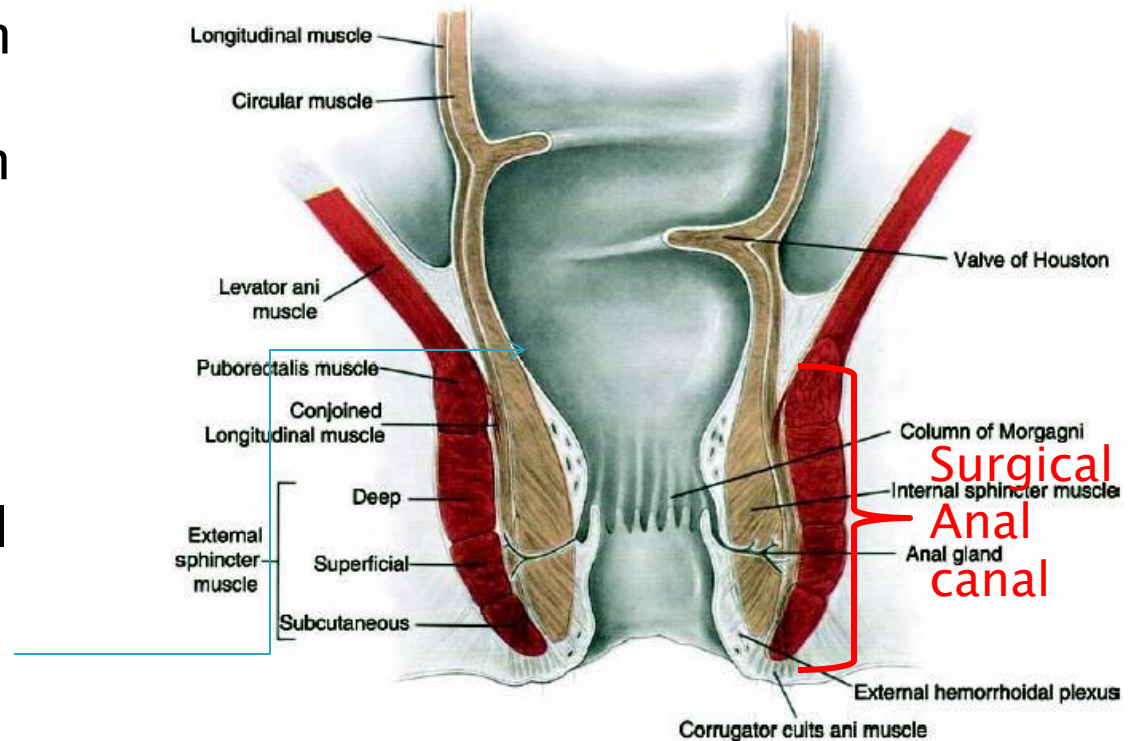
- ▶ If biopsy reveals Squamous cell carcinoma:
 - DRE
 - Anoscopy
 - Evaluate inguinal lymph nodes
 - FNA or biopsy of suspicious nodes to rule out reactive hyperplasia
 - CXR or Chest CT
 - Abdominal/pelvic CT or MRI
 - Consider HIV testing and CD4 count with patient consent
 - CD4 count <200 have worse outcomes. Start HAART.
 - For Women: pelvic exam to rule out GYN primary
 - Consider PET/CT (can upstage 17% of node-negative patients)

Pathology

- ▶ Squamous Cell Carcinoma (most common ~ 85%)
 - Keratinizing – 63%
 - Non-keratinizing – 23%
- ▶ Adenocarcinoma (10 – 15%)
 - Can behave more aggressively, worse prognosis
- ▶ Melanoma

Anatomy

- ▶ 3 – 4 cm long
- Composed of squamous epithelium primarily
- Transitions to rectum at the squamo-columnar junction
- Most HPV cancers occur at SC junction
- Dentate Line important anatomical division, but anorectal ring is important landmark on DRE

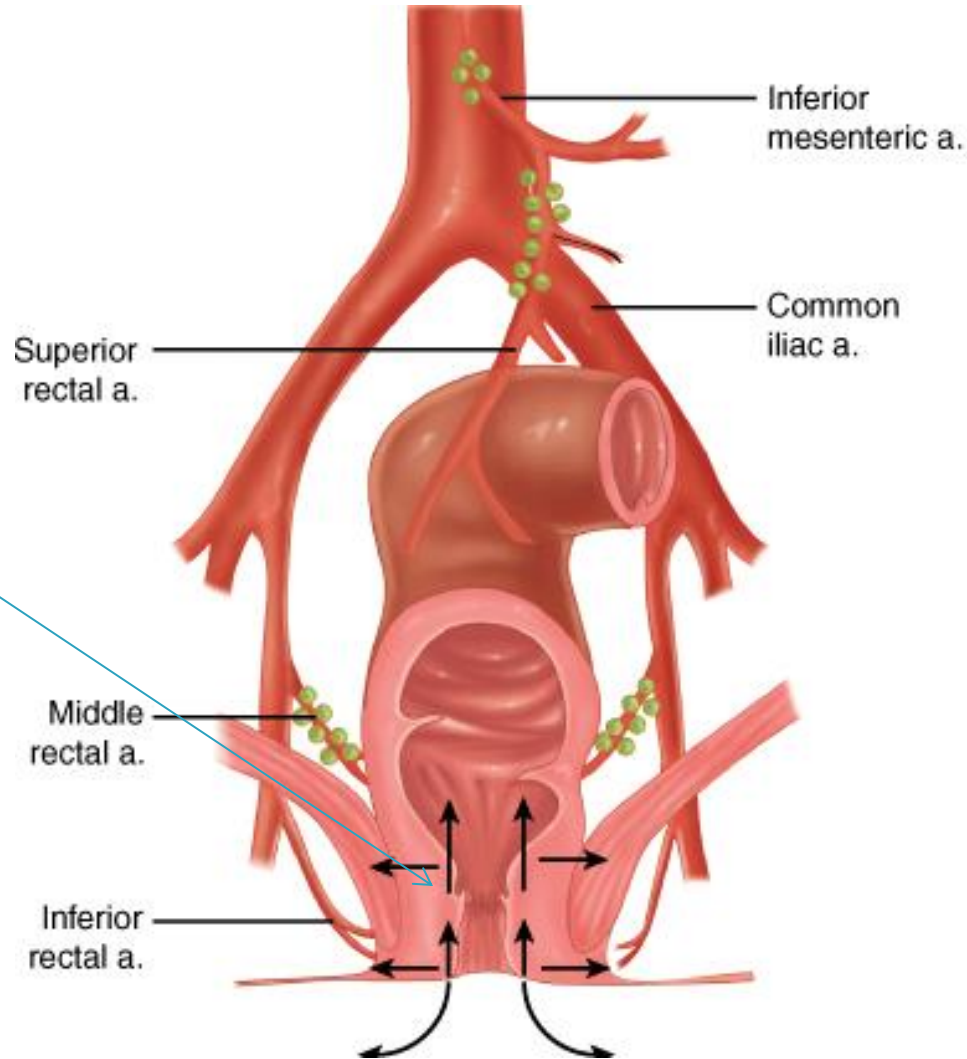


Lymphatic Drainage

- ▶ Upper 2/3
- ▶ -Superior Rectal Artery from the IMA
- ▶ -LNs drain more to internal iliac, IMA

- ▶ Dentate line separates drainage
- ▶ (not a palpable structure)

- ▶ Lower 1/3
- ▶ -Inferior Rectal Artery to Internal Pudendal Artery
- ▶ -LNs drain more to superficial inguinal LNs



AJCC 7th ed

Staging – is clinically based (including imaging)

T stage

T1 – 2cm or less

T2 – 2–5cm

T3 – >5cm

T4 – Invasion into adjacent structures (not including sphincter)

N stage

N1 – perirectal nodes

N2 – unilateral internal iliacs or superficial inguinal nodes

N3 – Bilateral disease, or involvement of both perirectal and inguinal nodes

Note – involvement of common iliac is M1 disease

Overall stage

Stage I – T1N0

Stage II – T2 or T3, N0

Stage IIIA – N1 or T4N0

Stage IIIB – T4N1 or any N2–N3

Stage IV – M1

- 50% localized
 - ~ 80% 5-year survival
- 30% with nodal involvement
 - ~ 60% 5-year survival
- 12 – 20% present with distant mets ~
 - 30% 5-year survival ¹

CT Simulation

- ▶ If treating with 3D CRT
 - Head-first supine position (can't boost inguinals with electrons in prone position)
 - Immobilize legs in frog-leg position to minimize skin folds.
 - Marker at anal verge, marker on palpable or biopsy-proven adenopathy.
 - Consider bubble wrap in skin folds for large patient to minimize autobolus effect.

- ▶ If treating with IMRT
 - Can position supine as above or prone in select patients,
 - important to choose most reproducible setup
 - (IMRT allows the risk of geographic miss if patient moves.)
 - Place markers similarly.

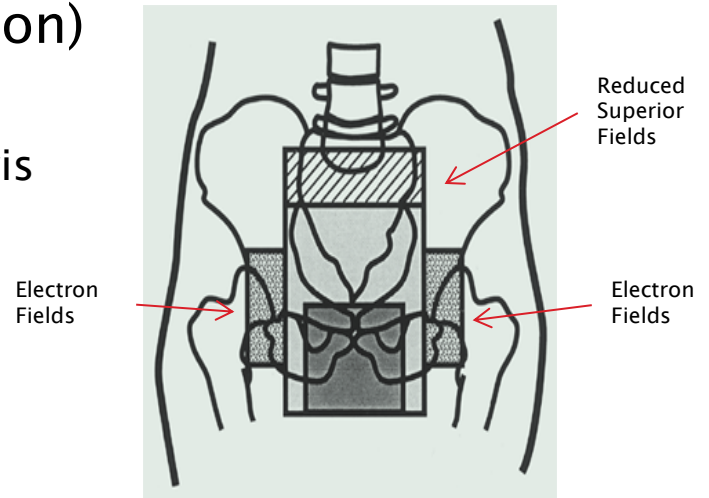
Planning

- ▶ DVH analysis for IMRT (Use max doses for 3DCRT)
 - Critical structures:
 - Small Bowel/Large Bowel (separate structures):
 - <200 cc above 30 Gy, <150 cc above 35 Gy,
 - <20 cc above 45 Gy, None above 50 Gy
 - Femoral Heads/Iliac Crests (separate structures):
 - <5% above 44Gy, <35% above 40Gy, <50% above 30Gy
 - Bladder:
 - <5% above 50Gy, <35% above 40Gy, <50% above 30Gy
 - Genitalia:
 - <5% above 40Gy, <35% above 30Gy, <50% above 20Gy

Treatment (RTOG 98-11)

Conformational Radiation Therapy (3D-CRT)

- ▶ 45 Gy in 25 fractions (180cGy/fraction)
- ▶ Initial Field (AP-PA) to 3060 cGy
 - Include anus, perineum, inguinal LNs, pelvis
 - Superior border - L5-S1
 - Inferior border - 2.5cm below tumor
 - Lateral - inguinal LNs
- ▶ Reduced Field (AP-PA) to 4500 cGy
 - Superior border - SI Joints (at 3060 cGy)
 - Lateral - Reduced fields to come off the inguinal LNs (at 3600 cGy)



Treatment (RTOG 0529)

▶ Radiation Therapy

- Tumor receives 5400 cGy in 30 fx
- Uninvolved LNs receives 4500 cGy in 30 fx
- Involved LN >3cm receives 5400 cGy in 30 fx
- Involved LN <3cm receives 5040 cGy in 30 fx

▶ Chemotherapy

- 5-FU infusions days 1 – 4 and days 29 – 32 (1000mg/m²)
- Mitomycin C on day 1 and 29 (10mg/m²)

RADIATION THERAPY ONCOLOGY GROUP

RTOG 0529

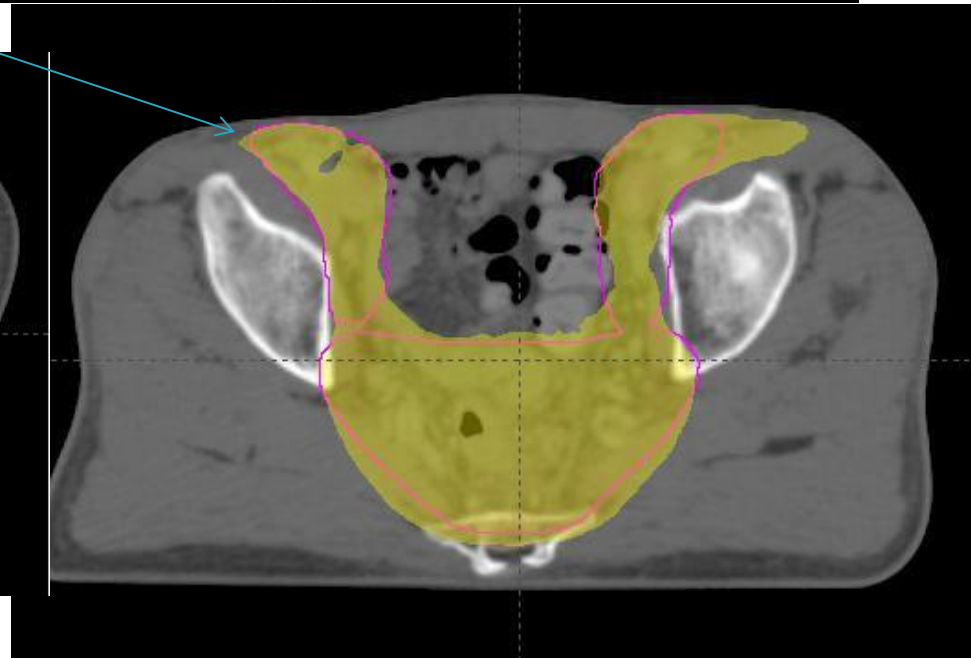
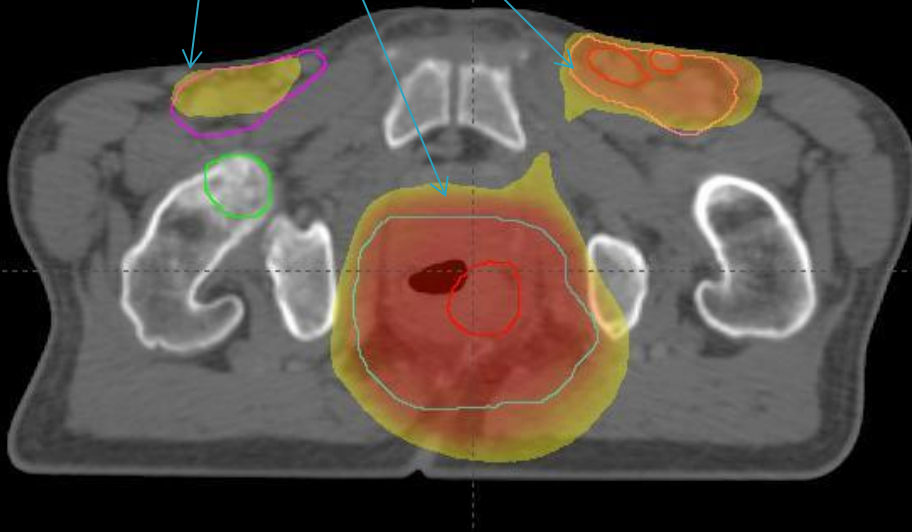
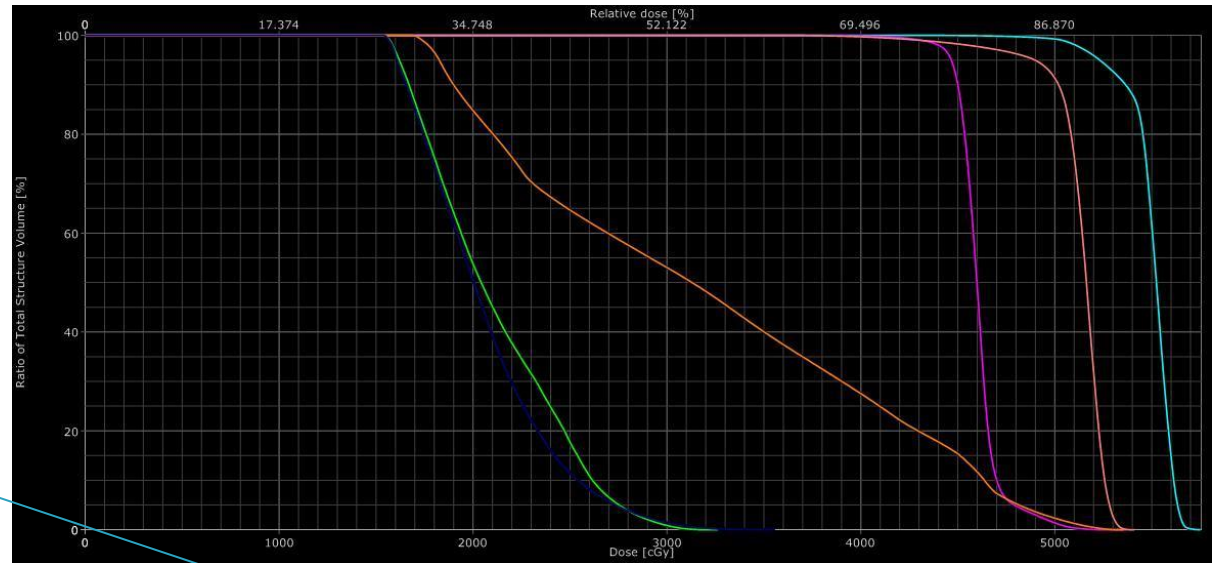
A Phase II Evaluation of Dose-Painted IMRT in Combination with 5-Fluorouracil and Mitomycin-C for Reduction of Acute Morbidity in Carcinoma of the Anal Canal

- Subjects: T1 – 4, N0 – 3, M0 – M1
- Design: Prospective study evaluating DP-IMRT + 5-FU + MMC using RTOG 0529 parameters
 - 5-FU infusions days 1 – 4 and days 29 – 32 (1000mg/m²)
 - Mitomycin C on day 1 and 29 (10mg/m²)
- PTVA – gross tumor volume, perirectal lymph nodes, anal canal with 2.5 cm expansion
- Uninvolved nodes – uninvolved inguinal, external iliac and internal iliac
- Nodes < or > 3cm – nodes specifically contoured
- ▶ [RTOG Anorectal Contouring Guidelines](#)


	PTVA	Uninvolved Nodes	Nodes < 3cm	Nodes > 3 cm
T2N0	5040 cGy 180 cGy/fx	4200 cGy 150 cGy/fx		
T3-4N0	5400 cGy 180 cGy/fx	4500 cGy 150 cGy/fx		
T2-4N+	5400 cGy 180 cGy/fx	4500 cGy 150 cGy/fx	5040 cGy 180 cGy/fx	5400 cGy 168 cGy/fx

DVH and Dose Distribution


- ▶ Femoral Heads
- ▶ Bladder
- ▶ PTV 5400
- ▶ PTV 5040
- ▶ PTV 4500
- ▶ Dose Color Wash:
 - 4500 cGy
 - 5040 cGy
 - 5400 cGy



Back to the Case

- ▶ We treated the patient using IMRT strictly following the RTOG 0529 protocol and RTOG contouring guidelines.
 - ▶ The patient tolerated treatment well without any moist desquamation at completion and is asymptomatic at 3 weeks out.
 - ▶ Our brave medical oncologists are treating him with full-dose chemo despite his CD4 count.
- 

Historical Context

- ▶ The disease was managed surgically until 1970s
 - With APR, requiring removal of sigmoid rectum, rectum, anal canal leaving stoma and requiring permanent colostomy
 - ▶ Early studies of neoadjuvant chemoradiation followed by surgery revealed high rates of pCR and led to primary chemoradiation
 - ▶ Optimal parameters for chemoradiation are now under investigation.
- 

Trials

▶ Neoadjuvant chemoRT → Surgery (Wayne State experience)

- Nigro ND. **Combined preoperative radiation and chemotherapy for squamous cell carcinoma of the anal canal.** Cancer. 1983 May 15;51(10):1826–9. PMID 6831348
 - 28 pts neoadjuvant RT 30 Gy /15fx (tumor+margin, pelvic +inguinal LN) + chemotherapy (5-FU/Mitomycin), followed by surgery 4–6 weeks later → 12 APR, 16 cCR, of APR (7 pCR)
 - **Take Home Point: chemoRT is great. Look below.**
- Leichman et al. **"Cancer of the anal canal. Model for preoperative adjuvant combined modality therapy."** Am J Med. 1985 Feb;78(2):211–5. PMID 3918441
 - 45 pts T2+ treated as above, initially APR (5/6 pCR), remaining avoided APR if neg Bx at 4–6 weeks. No relapses in biopsy negative patients.
 - **Take Home Point: Patients with pCR on biopsy don't need APR. (84%)**

▶ Surgery vs RT

- Swedish: Goldman S. **Management of anal epidermoid carcinoma--an evaluation of treatment results in two population-based series.** Int J Colorectal Dis. 1989 Dec;4(4):234–43. PMID 2614221
- Improvements in colostomy-free survival and comparable survival measures.
 - **Take Home Point: RT avoids colostomy while maintaining survival.**

Randomized Trials

▶ RT with and without Chemotherapy

- **EORTC: Bartelink H. Concomitant radiotherapy and chemotherapy is superior to radiotherapy alone in the treatment of locally advanced anal cancer: results of a phase III randomized trial of the European Organization for Research and Treatment of Cancer Radiotherapy and Gastrointestinal Cooperative Groups.** J Clin Oncol. 1997 May;15(5):2040–9. PMID 9164216
 - 110 pts, no T1N0, Arm 1) RT 45/25, if CR/PR → RT boost 15–20 Gy after 6 weeks or 2) RT 45/25 + CI 5-FU 750 mg/m² + MMC 15 mg/m² single bolus
 - LC 50% vs. 68% (SS); CFS 40% vs. 72% (SS); 5-year OS: 56% (NS), no toxicity differences
 - Take Home Point: ChemoRT is superior, standard of care with MMC/5FU
- **UKCCCR ACT I: Northover J. Chemoradiation for the treatment of epidermoid anal cancer: 13-year follow-up of the first randomised UKCCCR Anal Cancer Trial (ACT I).** Br J Cancer. 2010 Mar 30;102(7):1123–8. PMID 20354521
 - 585 pts, no T1N0, Rt 45/20–25 vs same RT + CI 5-FU 1000 mg/m² + Mitomycin 12 mg/m² bolus
 - If CR → boost 15 Gy, NR → APR. Local Failure primary endpoint.
 - 12 yr: LRC 41% vs 66% SS, CFS 20% vs 30%, OS 27% vs 33%. Majority recur in first 2 years.
 - Take Home Point: ChemoRT is superior, standard of care with MMC/5FU

Randomized Trials

▶ Treatment Intensification

- RTOG 98-11: Gunderson LL. **Long-term update of US GI intergroup RTOG 98-11 phase III trial for anal carcinoma: survival, relapse, and colostomy failure with concurrent chemoradiation involving fluorouracil/mitomycin versus fluorouracil/cisplatin.** J Clin Oncol. 2012 Dec 10;30(35):4344-51. PMID 23150707
 - 682 pts, Concurrent 5-FU/Mitomycin C vs. **Induction**/concurrent cisplatin/5-FU
 - (inclusion of induction chemo into cisplatin arm is big criticism of trial, increased package time)
 - Long-term results reveal 5yr DFS, 67.8% v 57.8% ,5yr OS, 78.3% v 70.7%; Both SS.
 - Take Home Point: Concurrent Mitomycin C demonstrates survival benefit over cisplatin. RT/5FU/MMC The Standard
- UKCCCR ACT II: James R. **A randomized trial of chemoradiation using mitomycin or cisplatin, with or without maintenance cisplatin/5FU in squamous cell carcinoma of the anus (ACT II).** J Clin Oncol 27:18s, 2009 (suppl; abstr LBA4009). Reported ASCO 2009
 - 4 arm trial, 940 pts, 2x2 design for concurrent CDDP vs MMC and 5FU/50.4Gy RT. 2nd rand for obs vs adj CDDP/5FU x 2 cycles
 - No difference in CFS (CR rates ~95%), secondary endpoints or hematologic toxicity.
 - Take Home Point: Mitomycin C remains standard of care over cisplatin. No adjuvant treatment.
- Intergroup ACCORD 03: Conroy T, Ducreux M, Lemanski C. **Treatment intensification by induction chemotherapy (ICT) and radiation dose escalation in locally advanced squamous cell anal canal carcinoma (LAAC): definitive analysis of the intergroup ACCORD-03 trial.** J Clin Oncol 2009;27(15s). (Part I of II): 176s (Abstr 4033). Reported at ASCO 2009
 - 4 arm trial, 307 pts, 2x2 design for 2 cycles induction cisplatin and 20Gy RT boost.
 - No differences in CFS (80-86%), primary endpoint, or secondary endpoints.
 - Take Home Point: No benefit of CFS for either induction chemo or higher RT dose.

Outcomes

	RTOG 0529 (2 years)	RTOG 9811 MMC/5-FU (5 year)	RTOG 9811 Cisplatin (5 year)
Disease-Free Survival	95%	~60%	~55%
Overall Survival	94%	75%	70%
Colostomy-Free Survival	90%	90%	81%
Distant Met-Free Survival	92%	85%	81%

Acute Toxicity with dose-painted IMRT

	Gr 0(%)	Gr 1(%)	Gr 2(%)	Gr 3(%)	Gr 4(%)
Derm	2 (5)	10 (23)	27 (63)	2 (5)	2 (5)
GI	9 (21)	13 (30)	18 (42)	3 (7)	0
Heme	4 (9)	4 (9)	9 (21)	21 (49)	5 (12)
GU	32 (74)	6 (14)	2 (5)	2 (5)	1 (2)

NCI CTCAE v3.0

Improved toxicity versus historical controls of RTOG 98-11 with promising outcomes.

DON'T BIOPSY FOR 12 WEEKS, EVEN IF RESIDUAL DISEASE!!! ONLY FOR PROGRESSIVE DISEASE.

There can be continued regression for up to 12 weeks.

Cummings et al IJROBP 1991.

An additional 9Gy with 5FU/MMC can be delivered to residual disease for **salvage** prior to APR (RTOG 87-04)

References

1. <http://seer.cancer.gov/statfacts/html/anus.html>
2. Melbye M, Rabkin C, Frisch M, et al: [Changing patterns of anal cancer incidence in the United States, 1940–1989](#). *Am J Epidemiol* 1994; 139(8):772–780.
3. Melbye M, Cote TR, Kessler L, et al: [High incidence of anal cancer among AIDS patients. The AIDS/Cancer Working Group](#). *Lancet* 1994; 343(8898):636–639.
4. Myerson RJ, Karnell LH, Menck HR: [The National Cancer Data Base report on carcinoma of the anus](#). *Cancer* 1997; 80(4):805–815.
5. Tanum G, Tveit K, Karlsen KO: [Diagnosis of anal carcinoma—doctor's finger still the best?](#). *Oncology* 1991; 48(5):383–386.
6. Ajani, J et al. Fluorouracil, Mitomycin, and Radiotherapy vs Fluorouracil, Cisplatin, and Radiotherapy for Carcinoma of the Anal Canal. *JAMA*. 2008; 299(16):1914 – 1921.
7. Nguyen BT, Joon DL, Khoo V, et al: [Assessing the impact of FDG–PET in the management of anal cancer](#). *Radiother Oncol* 2008; 87(3):376–382.
8. Iagaru A, Kundu R, Jadvar H, et al: [Evaluation by 18F–FDG–PET of patients with anal squamous cell carcinoma](#). *Hell J Nucl Med* 2009; 12(1):26–29.
9. Trautmann TG, Zuger JH: [Positron emission tomography for pretreatment staging and posttreatment evaluation in cancer of the anal canal](#). *Mol Imaging Biol* 2005; 7(4):309–313.
10. Cotter SE, Grigsby PW, Siegel BA, et al: [FDG–PET/CT in the evaluation of anal carcinoma](#). *Int J Radiat Oncol Biol Phys* 2006; 65(3):720–725.
11. Winton E, Heriot AG, Ng M, et al: [The impact of 18–fluorodeoxyglucose positron emission tomography on the staging, management and outcome of anal cancer](#). *Br J Cancer* 2009; 100(5):693–700.
12. Schwarz JK, Siegel BA, Dehdashti F, et al: [Tumor response and survival predicted by post–therapy FDG–PET/CT in anal cancer](#). *Int J Radiat Oncol Biol Phys* 2008; 71(1):180–186.
13. Leichman L, Nigro N, Vaitkevicius VK, et al: [Cancer of the anal canal. Model for preoperative adjuvant combined modality therapy](#). *Am J Med* 1985; 78(2):211–215.
14. Nigro ND, Seydel HG, Considine B, et al: [Combined preoperative radiation and chemotherapy for squamous cell carcinoma of the anal canal](#). *Cancer* 1983; 51(10):1826–1829.
15. Bartelink H, Roelofsens F, Eschwege F, et al: [Concomitant radiotherapy and chemotherapy is superior to radiotherapy alone in the treatment of locally advanced anal cancer. Results of a phase III randomized trial of the European Organization for Research and Treatment of Cancer Radiotherapy and Gastrointestinal Cooperative Groups](#). *J Clin Oncol* 1997; 15(5):2040–2049.
16. UKCCCR Anal Cancer Trial Working Party : [Epidermoid anal cancer. Results from the UKCCCR randomised trial of radiotherapy alone versus radiotherapy, 5–fluorouracil, and mitomycin.. UK Co–ordinating Committee on Cancer Research](#). *Lancet* 1996; 348(9034):1049–1054.
17. Flam M, John M, Pajak TF, et al: [Role of mitomycin in combination with fluorouracil and radiotherapy, and of salvage chemoradiation in the definitive nonsurgical treatment of epidermoid carcinoma of the anal canal. Results of a phase III randomized intergroup study](#). *J Clin Oncol* 1996; 14(9):2527–2539.
18. Peters RK, Mack TM: [Patterns of anal carcinoma by gender and marital status in Los Angeles County](#). *Br J Cancer*. 1983 Nov;48(5):629–36.
- 19.