

CRANIOPHARYGIOMA

Rachel Brehm (MS4), Gabriel Vidal, MD (PGY-5)

Faculty Advisor: Michael Confer, MD

Department of Radiation Oncology

University of Oklahoma Health Sciences Center

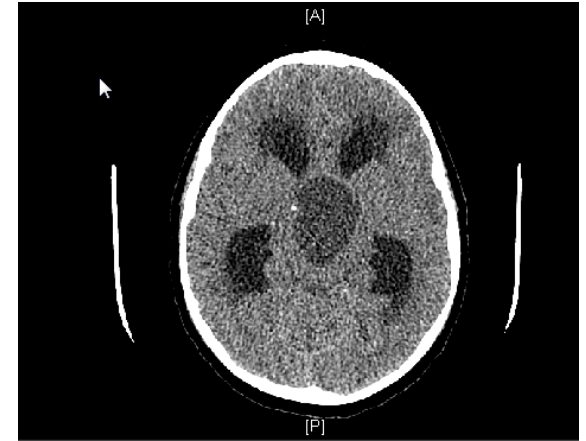
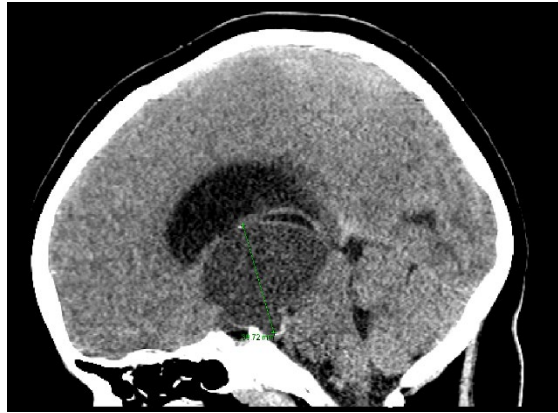
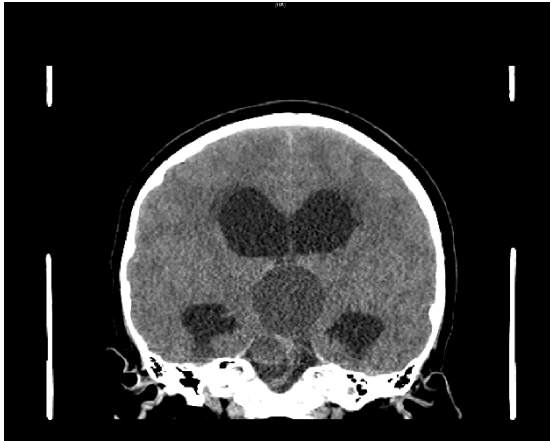
Case Presentation

- 5 yo boy with no significant PMH
- Patient seen by ophthalmology due to worsening history of vision changes, headaches, and intermittent vomiting.
- Exam was significant for papilledema & asymmetric visual field deficits.
- Patient was sent to OU Children's Hospital for CT head.

Case Presentation

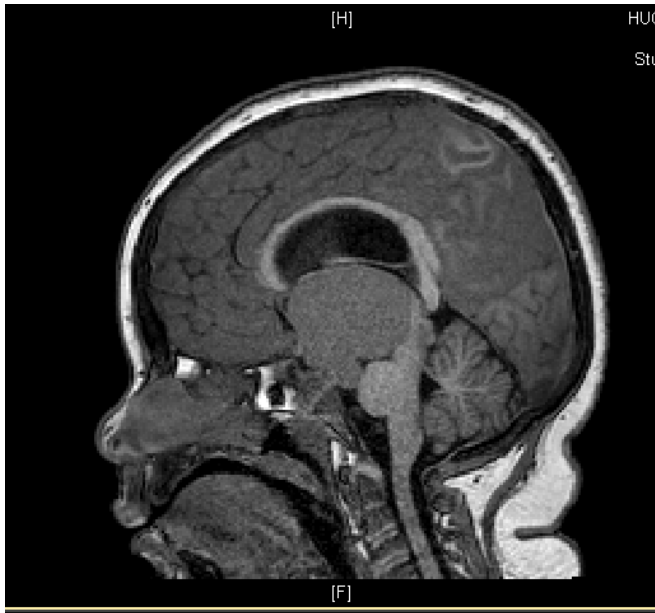
- 2-3 month history of:
 - Daily headaches
 - Nausea & vomiting 2-3x per week
 - Clumsiness and falls
 - Increased lethargy and fatigue
- No signs or symptoms of infection

Imaging CT Head

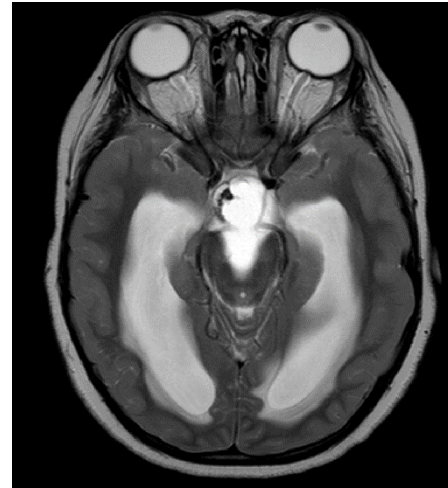


- A large midline, heterogeneous, calcified, hypodense/cystic suprasellar mass causing obstructive hydrocephalus.
- Mass measured 4 cm craniocaudal, 3.3 cm transverse and 4.3 cm AP.

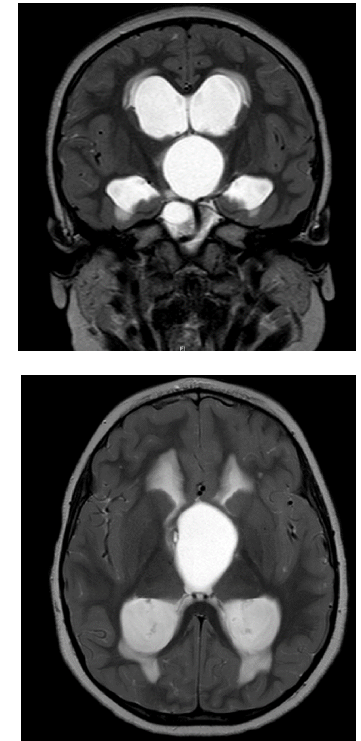
Imaging – MRI



T1 post-contrast



T2 sequence



- Large suprasellar cystic mass with mass effect on the third ventricle midbrain, and pons.
- The mass causes biventricular hydrocephalus with transependymal CSF flow.

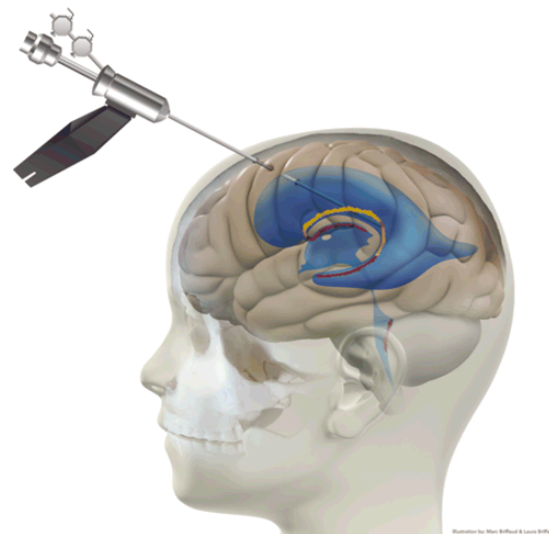
Differential Diagnosis:

- Supratentorial mass – “COP GEM”
 - Craniopharyngioma
 - Optic Glioma
 - Pituitary Adenoma
 - Germ Cell Tumor
 - Ependymoma
 - Meningioma
- Differentiate with labs (biopsy rarely indicated)

Workup - Labs

- CBC / CMP
- Test for diabetes insipidus (DI)
 - Urine Osmolality
 - Water Deprivation Test
- Thyroid studies
- GH / IGF-1
- FSH / LH
- Prolactin
- bHCG & AFP
- AM Cortisol
- Cortisol Stimulation

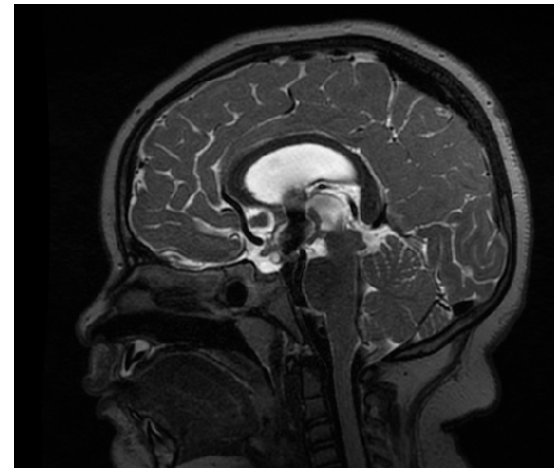
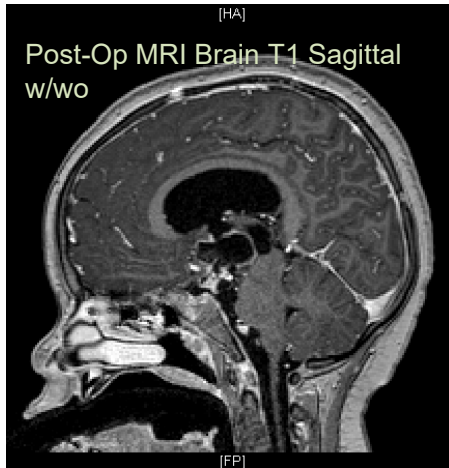
Treatment – Our Case



- Neurosurgery – Left frontal endoscopic fenestration of cyst, debulking of tumor, endoscopic third ventriculostomy (right) and septum pellucidotomy
- Path – confirmed craniopharyngioma, adamantinomatous type
- Development of DI, requiring DDAVP x 2
- Post op Proton Beam Therapy

Treatment Planning - Simulation

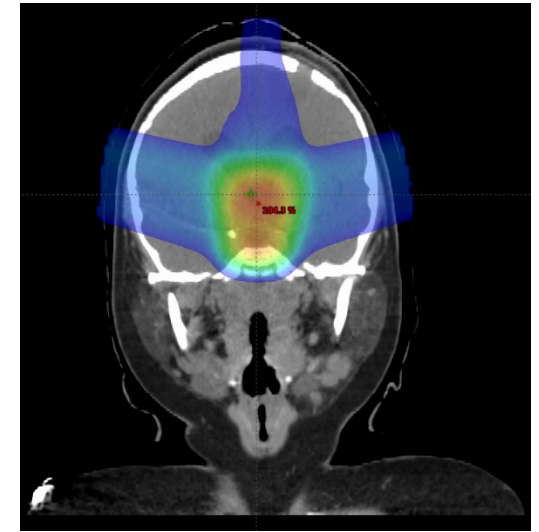
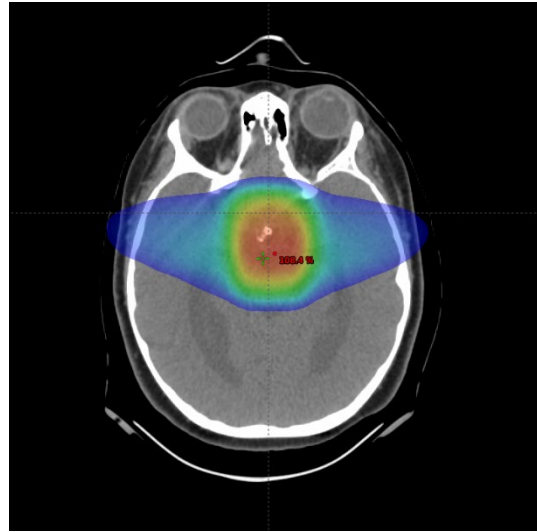
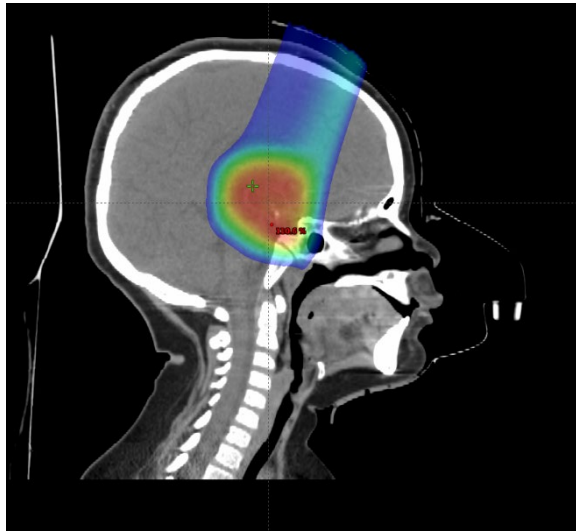
- Position: Supine, arms down.
- Immobilization: Thermoplastic head mask
- General anesthesia per team discretion. Younger patients are more likely to require sedation.



Treatment Planning Details

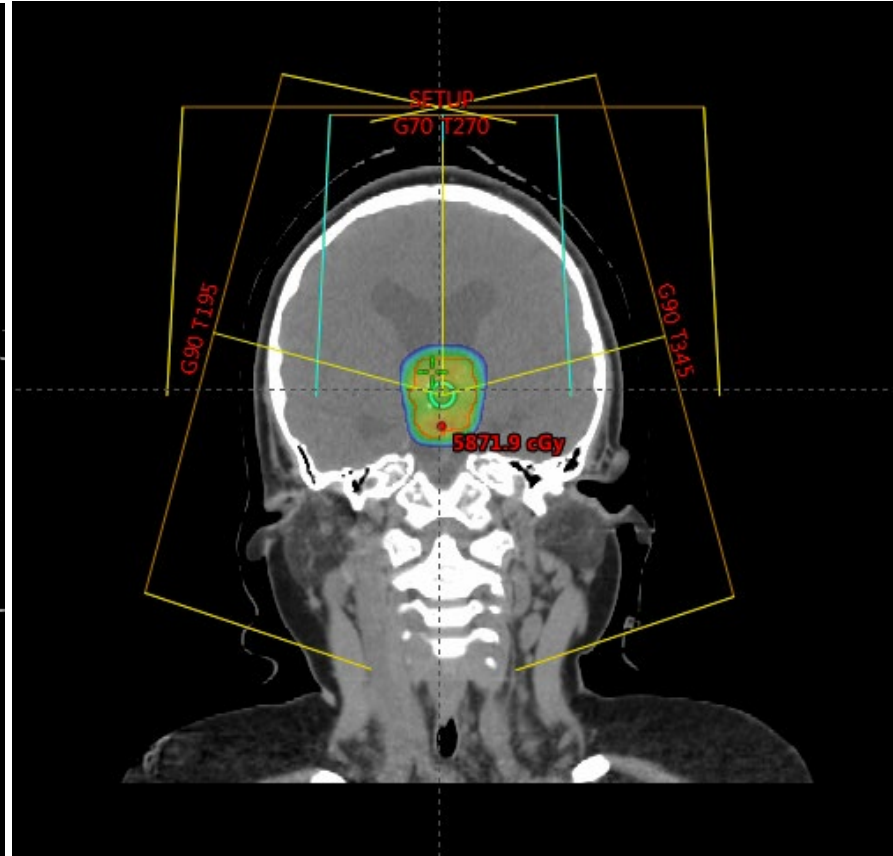
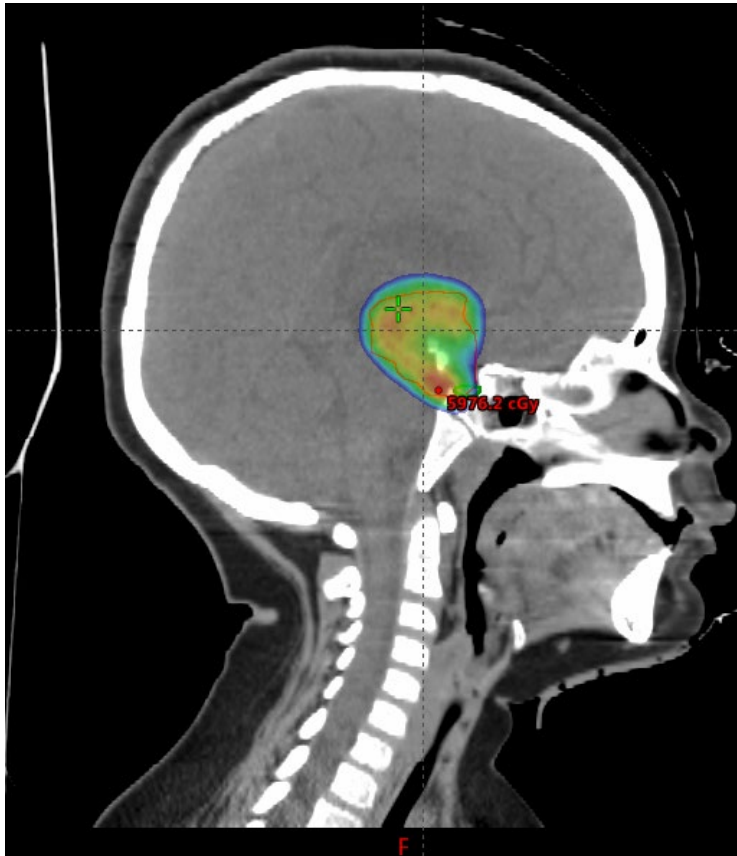
- Target volume:
 - GTV: Residual solid tumor and cystic volume.
 - CTV: GTV expansion of 5-mm, anatomically constrained.
 - 0-mm used with fractionated stereotactic radiotherapy in Heidelberg
 - 2-mm PTV margin
 - PTV: 3-5 mm geometrically expanded
- Dose: 50-54 Gy at 1.8 Gy per fraction.
- Repeat MRI to monitor cyst changes every week for the first 3 weeks.
- Single-fraction radiosurgery possible for minimal residual tumor or recurrence < 2 cm.
- Our case received 54 Gy in 30 fractions

Treatment Plan Evaluation

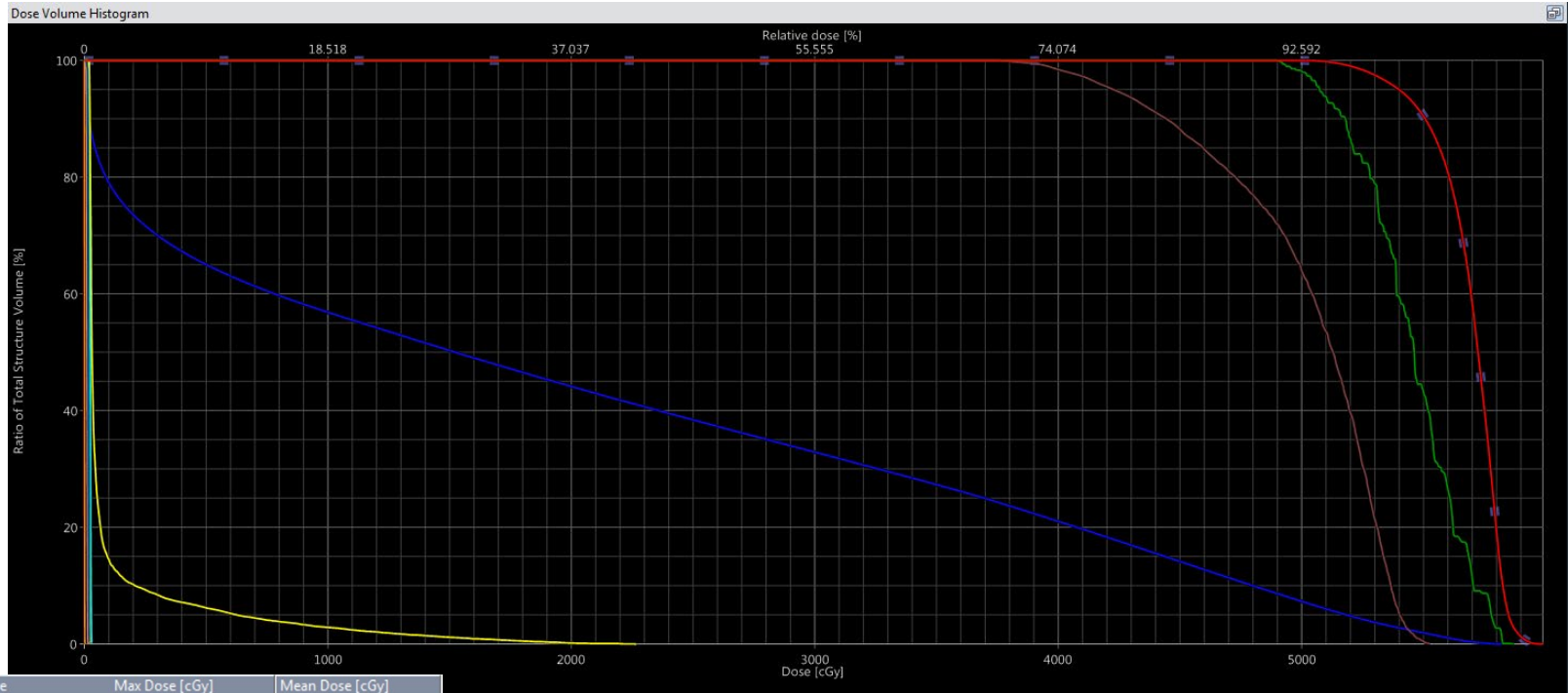


Three beam setup: Two opposed lateral beams and one superior/anterior beam.

Treatment Plan - Evaluation



Treatment Plan – Dose Volume Histogram



Show DVH	Structure	Max Dose [cGy]	Mean Dose [cGy]
<input checked="" type="checkbox"/>	CTV_5400	5990.5	5691.5
<input checked="" type="checkbox"/>	GTV_planningCT	5980.7	5725.5
<input checked="" type="checkbox"/>	PITUITARY	5874.0	5450.5
<input checked="" type="checkbox"/>	BRAINSTEM	5826.4	1997.5
<input checked="" type="checkbox"/>	OPTIC CHIASM	5531.3	5012.6
<input checked="" type="checkbox"/>	RT OPTIC NERVE	2266.4	114.5
<input checked="" type="checkbox"/>	LT OPTIC NERVE	2035.6	126.0
<input checked="" type="checkbox"/>	LT COCHLEA	30.0	24.0
<input checked="" type="checkbox"/>	LT ORBIT	26.4	15.3
<input checked="" type="checkbox"/>	RT ORBIT	24.8	13.4
<input checked="" type="checkbox"/>	RT COCHLEA	19.5	15.6
<input checked="" type="checkbox"/>	LT LENS	16.0	13.5
<input checked="" type="checkbox"/>	RT LENS	15.4	11.6
<input checked="" type="checkbox"/>	CERVICAL CORD	2.5	0.6

August 22, 2022

ASSOCIATION OF RESIDENTS IN RADIATION ONCOLOGY

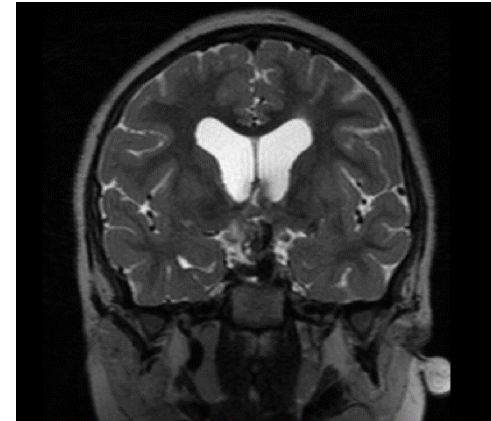
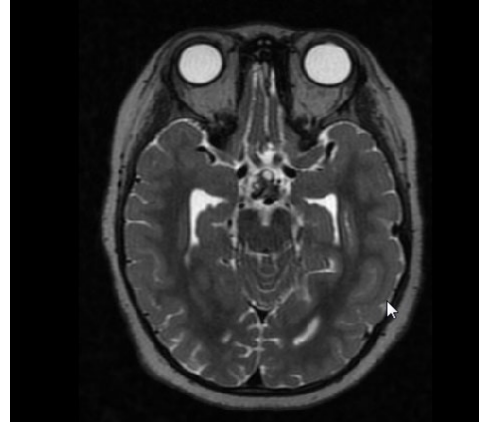


Treatment Plan – Dose Constraints

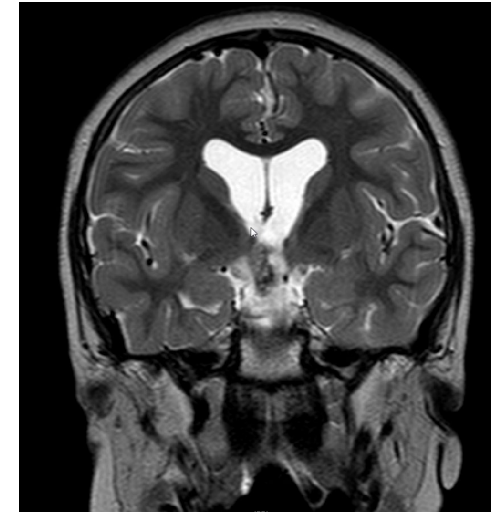
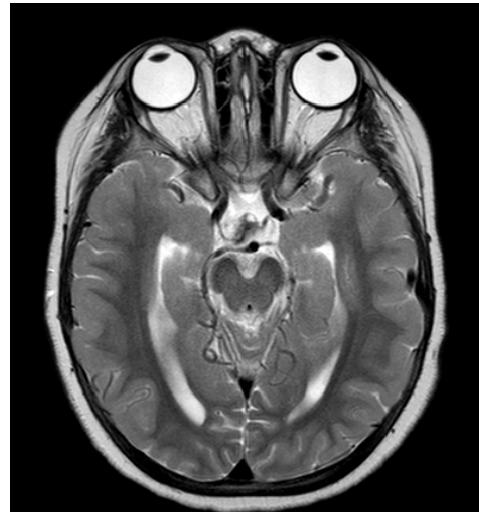Structure	Metric	Default
Optic Chiasm, Optic Nerves	Max	< 55 Gy
Cochlea	Mean	< 35 Gy
Brainstem	Max (0.03 cm ³)	< 60 Gy
Retina	Max	< 50 Gy
Lacrimal gland	Mean	< 34 Gy
Lens	Max	< 6 Gy
Spinal Cord	Max (1 cm ³)	< 50 Gy
Hippocampus	Mean (ALARA)	< 6 Gy

Our Case – 1 & 3 months post op

1mo p/o



3mo p/o



Our Case – 2 years post op

Morbidity & Side Affects:

- Diabetes Insipidus
- Hypothyroidism
- Obesity
- Sleep Apnea
- No tumor reoccurrence to date!

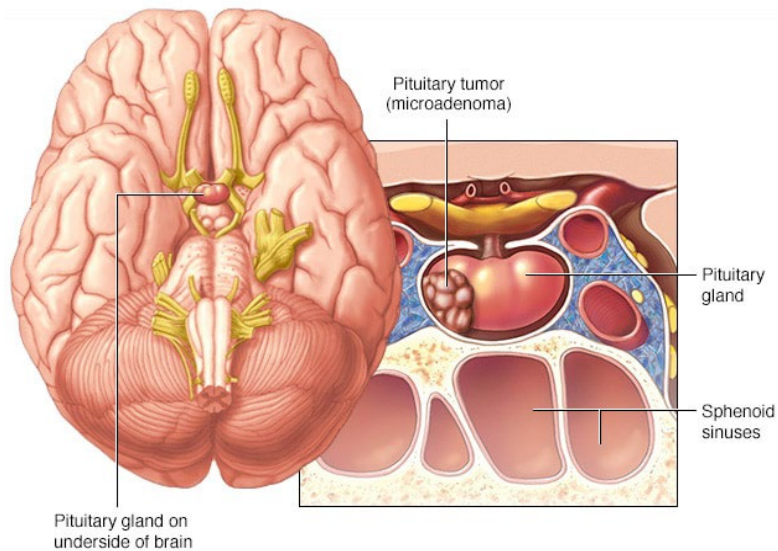
Craniopharyngioma: Epidemiology

- **5-10% of all pediatric tumors**
- 56% of tumors in sellar/chiasmatic region in pediatric patients
- Bimodal distribution: 5-10yo & 55-65yo
- Overall **incidence** in the United States per 100,000 is **0.17–0.2** with a slightly higher incidence in African Americans

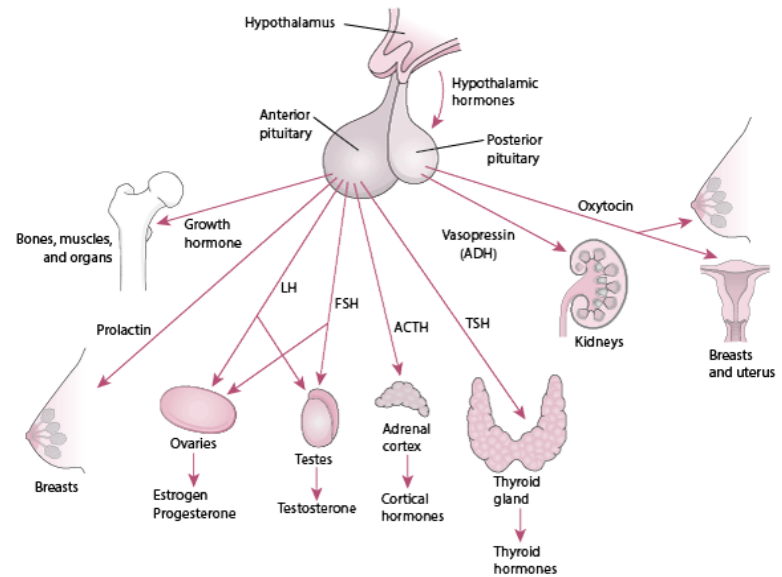
Pathophysiology

- Locally invasive tumors typically occurring in the suprasellar region
 - primary PEDIATRIC subtype: Adamantinomatous
- Originate from Rathke's Pouch- an Ectodermal outpouching from the roof of the mouth, eventually forming the adenohypophysis
- Cysts produce a “motor oil” appearing fluid – proteinaceous with cholesterol crystals

Pituitary Gland: Review



© MAYO FOUNDATION FOR MEDICAL EDUCATION AND RESEARCH, ALL RIGHTS RESERVED.

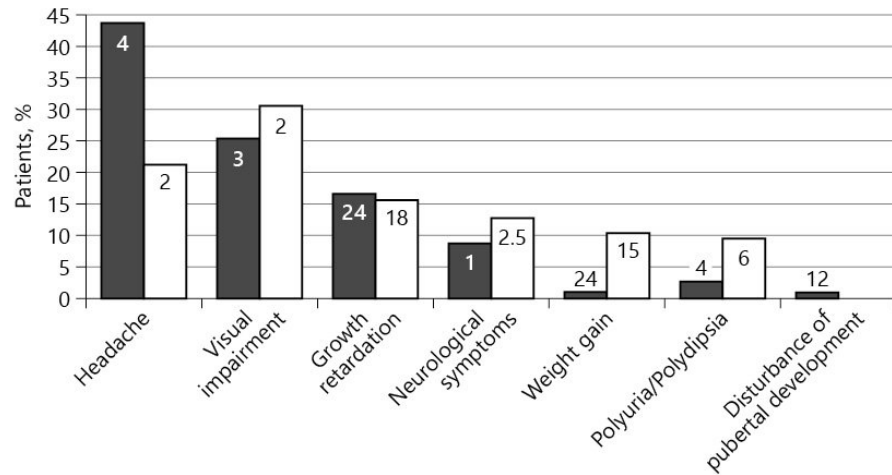


© 2020 Merck Sharp & Dohme Corp., a subsidiary of Merck & Co., Inc., Kenilworth, NJ, USA

Typical Presentation

- #1 Mass Effect
 - Vision, Headache, N/V, obstructive hydrocephalus
- Endocrinopathies
 - GH in children – short stature
 - GnRH in adolescents – delayed puberty, ED, amenorrhea
 - TSH – cold intolerance, fatigue, skin & hair
 - ACTH – hypoglycemia, myalgias, fatigue, weight
 - DI – polydipsia

• Black column – symptom occurrence before treatment (% patients)
• White column – presenting symptom (% patients)
• Number insert in column – median time (months) from appearance until dx



Prognosis & Tx

Prognosis

- Mortality: 20 year survival from childhood onset are 87-95%
- Morbidity: high - many consider CP a “chronic disease”, significant QOL impairment from hypothalamic obesity & hormonal dysfunction
- Good prognostic factors – an early catch, no involvement of the hypothalamus, maximum salvage of optic chiasm

Treatment Approach

- Gold Standard - complete resection w radio-oncologic intervention
 - Commonly a combined NES/ENT resection.
- Radiation Therapy is a mainstay in reducing recurrences
- Increasing favor of Proton Beam Therapy in CP

Treatment Options

Gross Total Resection

- High risk of hypopituitarism
 - Diabetes Insipidus
 - Growth Restriction
 - Vision Loss
- Greater IQ loss
- Disease Free Survival
 - 70-85%, 20% failure

Subtotal + Radiation Therapy

- STR alone
 - Disease Free Survival <50%
- STR + RT
 - Disease Free Survival 85-90%
 - At 5yrs, PFS of 98%
- Can defer RT for kids <5-7yo

[[Stripp IJROBP '04](#), [Varlotto NOP '16](#)]

Treatment Approaches – Differing Opinions

- Journal of Neurosurgery on RT modalities:
 - GTR and CD + PBT presented similar rates of 5-year PFS. Hypopituitarism and DI rates were higher with GTR, but the rate of HyOb was similar among different treatment modalities. PBT may reduce the burden of hypopituitarism and DI, although radiation carries a risk of potential serious complications, including progressive vasculopathy and secondary malignancy.
- Journal of Surgical Research:
 - There were no significant differences between the GTR and STR with RT groups when the authors compared overall survival and progression-free survival...

Treatment Approaches – Differing Opinions

- Canadian Journal of Neurological Sciences:
 - STR + RT had a significantly higher progression free survival (100%) when compared to GTR alone (69%) and STR alone (18%) ¹
 - Our study underscores the importance of RT for local control and suggests that STR + RT should be considered a viable option in the management of these tumors as it may be associated with improved PFS compared to surgery alone
- Neuro-Oncology:
 - Limited surgery and CRT using photons results in *excellent* tumor control ⁴

Follow Up

- MRI and visit
 - Q 3 months for 1 year
 - Q 6 months for 2-3 years
 - Annually thereafter
- Neurocognitive testing Q1-2 years until stable
- Endocrine follow up every 6 months
- Annual Ophthalmology evaluation with visual field testing

Complications / Side Effects

- Decreased IQ
- Hypothalamic obesity
- Panhypopituitarism (Most Common)
- In descending order:
 - Growth Restriction, Hypopituitarism, Cushing's, Hypogonadism, & sleep disorders
- Secondary malignancy, necrosis, vasculopathy (such as Moyamoya), and permanent neurologic deficits ⁴
- Vision changes or loss
- Worse prognostic factors:
 - Rapid development of DI, hypothalamic involvement or resection, greater extent of optic chiasm effected

Review: Craniopharyngioma

- This is a pediatric suprasellar rare, benign brain tumor, with calcifications and cystic components commonly seen on imaging, along with pituitary/hormonal, mass effect and visual disturbances.
- Treatment mainstay is surgical resection aimed at gross removal with adjuvant radiotherapy.
- Ongoing research with respect to radiation modalities shows great promise.

Further Reading: Current Research

- A cohort study (n=40) compared the two adjuvant radiation modalities most commonly used for recurrent and residual craniopharyngioma. Gamma Knife Radiosurgery vs Fractionated Radio Therapy. “The authors' results revealed that precise radiosurgery dose planning can mediate the subsequent increase in BMI. There is every indication that meticulous GKRS treatment is an effective approach to treating craniopharyngioma while also reducing the risk of hypothalamic obesity.”⁶
- A case control on the long term results of CyberKnife treatment- “it’s long-term results are evident, and the good growth control and low adverse effects are impressive. We are confident that we can maintain good treatment results by combining conservative surgical resection with minimal complications and CyberKnife treatment for new patients in the future.”⁷
- The use of Proton Beam Therapy on craniopharyngiomas offers the same benefits evident in the treatment of other malignances and is clinically analogous to IMRT. Although IMRT and PBT have similar clinical outcomes, PBT has the potential to reduce brain and total body irradiation, therefore reducing the risk of complications and secondary cancer formation.⁹

References

1. Ravindra VM, Okcu MF, Ruggieri L, et al. Comparison of multimodal surgical and radiation treatment methods for pediatric craniopharyngioma: long-term analysis of progression-free survival and morbidity. *Journal of Neurosurgery: Pediatrics*. 2021;28(2):152-159. doi:10.3171/2020.11.PEDS20803
2. Müller H, L: The Diagnosis and Treatment of Craniopharyngioma. *Neuroendocrinology* 2020;110:753-766. doi:10.1159/000504512
3. Khriguian, J., Tolba, M., Khosrow-Khavar, F., Kordlouie, S., Guiot, M., Abdulkarim, B., . . . Panet-Raymond, V. (2022). Is Postoperative Radiotherapy Needed in the Management of Adult Craniopharyngiomas? *Canadian Journal of Neurological Sciences / Journal Canadien Des Sciences Neurologiques*, 1-7. doi:10.1017/cjn.2022.28
4. Edmonston DY, Wu S, Li Y, Khan RB, Boop FA, Merchant TE. Limited Surgery and Conformal Photon Radiation Therapy for Pediatric Craniopharyngioma: Long-term Results from the RT1 Protocol. *Neuro-oncol*. 2022;. doi:10.1093/neuonc/noac124, 10.1093/neuonc/noac124
5. Varlotta JM, Flickinger JC, Kondziolka D, Lunsford LD, Deutsch M. External beam irradiation of craniopharyngiomas: long-term analysis of tumor control and morbidity. *Int J Radiat Oncol Biol Phys*. 2002;54(2):492-499. doi:10.1016/s0360-3016(02)02965-6
6. Chou CL, Chen HH, Yang HC, et al. Effects of stereotactic radiosurgery versus conventional radiotherapy on body mass index in patients with craniopharyngioma [published online ahead of print, 2021 May 14]. *J Neurosurg Pediatr*. 2021;1-7. doi:10.3171/2020.12.PEDS20165
7. Ohhashi G, Miyazaki S, Ikeda H, et al. (March 08, 2020) Postoperative Long-term Outcomes of Patient with Craniopharyngioma Based on CyberKnife Treatment. *Cureus* 12(3): e7207. doi:10.7759/cureus.7207
8. Thomas E Merchant, DO, PhD, Drucilla Y Edmonston, MD, Shengjie Wu, MS, Yimei Li, PhD, Frederick A Boop, MD, Robert H Lustig, MD, MSL, Endocrine Outcomes after Limited Surgery and Conformal Photon Radiation Therapy for Pediatric Craniopharyngioma: Long-term Results from the RT1 Protocol, *Neuro-Oncology*, 2022;, noac115, <https://doi.org/10.1093/neuonc/noac115>
9. Lara-Velazquez M, Mehkri Y, Panther E, Hernandez J, Rao D, Fiester P, Makary R, Rutenberg M, Tavanaiepour D, Rahmathulla G. Current Advances in the Management of Adult Craniopharyngiomas. *Current Oncology*. 2022; 29(3):1645-1671. <https://doi.org/10.3390/curroncol29030138>
10. Weil, A. G., Fallah, A., Chamiraju, P., Ragheb, J., & Bhatia, S. (2016). Endoscopic third ventriculostomy and choroid plexus cauterization with a rigid neuroendoscope in infants with hydrocephalus, *Journal of Neurosurgery: Pediatrics* PED, 17(2), 163-173. Retrieved Jul 27, 2022, from <https://thejns.org/pediatrics/view/journals/j-neurosurg-pediatr/17/2/article-p163.xml>

Please provide feedback regarding this case or other ARRO cases to arrocase@gmail.com