

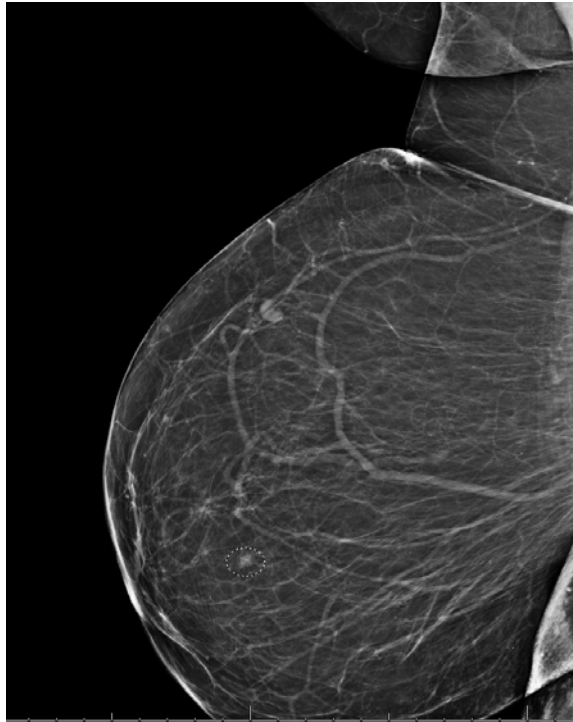
Accelerated Partial Breast Irradiation (APBI)

Hadley Walsh Ressler (MS1), Asona Lui, MD PhD (PGY3)

Faculty Mentor: Karen Tye, MD

Wake Forest Baptist Health, NC, and UC San Diego Health, CA

Clinical Presentation



- 70 year old female underwent annual bilateral screening mammogram
 - Abnormality was noted in the right breast
- Patient was otherwise asymptomatic with no associated skin changes or nipple discharge

Patient History

- Past Medical History
 - Hodgkin lymphoma s/p Mantle Field radiation of unknown dose/duration in 1988, Bone marrow transplant
- Past Surgical History
 - Umbilical Hernia Repair in 2021
- Medications
 - None
- No known drug allergies

Patient History (con't)

- Gynecologic History
 - G2P2, 25 years old at first pregnancy
 - Menarche at age 13, menopause at age 39
 - She has not used oral contraceptives or hormone replacement therapy previously
- Social History
 - Caring for relative
 - Widow
 - Retired from work
 - No alcohol or tobacco use
- Family History
 - Mother: breast cancer at age 68
 - Father and paternal uncle: colon cancer

Physical Exam

- Vitals: BP 131/56, HR 75, RR 16, BMI 35.5
- General: Well developed, well nourished, in no acute distress.
- Lymphatics: No palpable bilateral cervical, axillary, or supraclavicular adenopathy
- CV: Regular rate, extremities well-perfused.
- Resp: Normal respiratory effort.
- Breast: In supine position; biopsy site in lateral right breast well healed; no palpable masses.
- Neurologic: CN II-XII grossly intact. No focal neurologic deficits appreciated.

Diagnostic Workup

- Diagnostic right mammogram
 - 0.5 cm focal asymmetry without associated calcifications
- Targeted US of right breast
 - On diagnostic mammogram and ultrasound 8:00 4 cm from the nipple there was a nodular asymmetry with partially well circumscribed and partially indistinct margins, that was hypoechoic with internal vascularity seen
- US-guided core needle biopsy
 - Invasive mucinous carcinoma
 - ER100, PR>90, HER2 1+, H2n- by IHC
 - Intermediate grade

Multidisciplinary Care

- Patient was seen in multidisciplinary clinic pre-operatively, she was interested in oncoplastic reduction
- Discussed options for local treatment with surgeon. if oncoplastic reduction to occur, accurate visualization of tumor bed essential (clips and/or seroma) to be candidate for APBI
- Presented options for local treatment: lumpectomy with omission, whole breast irradiation (WBI), or accelerated partial breast irradiation (APBI)
- The patient elected to undergo APBI with IMRT following lumpectomy

Introduction to APBI

- Whole breast irradiation (WBI)
 - Standard of care after breast conservation surgery for early stage breast cancer.
- APBI introduced with possible advantages over WBI while providing equivalent LC in low risk patients
 - Shortened treatment course
 - Typically 2-5 days vs 3-5 weeks
 - Decreased radiation dose/toxicity
 - Reduced exposure to heart, lung, ribs.

Which patients should be considered for APBI?

- Must be candidates for breast-conserving therapy
 - No prior radiotherapy
 - No history of collagen vascular diseases
 - Not pregnant
- Consensus guidelines from ASTRO in 2017 put patients into 3 classes
 - Suitable
 - Cautionary
 - Unsuitable

ASTRO consensus statement for APBI

	Suitable (Pt meets <u>all</u> criteria)	Cautionary (Pt meets <u>all</u> criteria)	Unsuitable (Pt meets <u>any</u> criteria)
Age	≥ 50	40-49	< 40
Tumor Size, T stage	≤ 2 cm, Tis or T1	2.1 – 3 cm, T0 or T2	> 3 cm, T3-T4
N stage, surgery	pN0 (SNBx or ALND)		pN1-3 or no nodal surgery
Margins	Negative (≤ 2 mm)	Close (< 2 mm)	Positive
LVSI	No	Limited/focal	Extensive
ER status	Positive	Negative	
Centricity	Unicentric	Microscopic multi-centricity	Present
Histology	Invasive ductal or favorable histology	Invasive lobular	
EIC or Pure DCIS	If screen detected, low to intermediate grade, size ≤2.5 cm, resected with margins negative at >3mm	≤ 3 cm and does not meet criteria for suitable	> 3 cm
Associated LCIS	Allowed		
Neoadjuvant Tx	Not allowed		Received

ASTRO vs. ABS vs. ASBS

Comparison of criteria for approved group

	ASTRO "Suitable" (2017)	ABS (2013)	ASBS (2013)
Age	≥ 50	≥ 50	≥ 45 (IDCA), ≥ 50 (DCIS)
Tumor Size, T stage	≤ 2 cm, Tis or T1	≤ 3 cm	≤ 3 cm
N stage, surgery	pN0 (SNBx or ALND)	pN0 (SNBx or ALN level I/II)	pN0 (SNBx)
Margins	Negative (≤ 2 mm)	Negative microscopic	Negative microscopic
Centricity	Unicentric, clinically unifocal	Unifocal	
LVSI	Not present	Not present	Not present
Histology	Invasive ductal or favorable histo	Any invasive	Any Invasive or DCIS

LIMES (LVSI, ILC, Margins Close, ER-, and Size > 2cm)

APBI Methodology

- Multiple methods available
 - Brachytherapy
 - Multi-catheter interstitial (High, Low, or Pulsed dose rates)
 - SAVI
 - Balloon catheterization (Mammosite, Contura)
 - External beam (EBRT)
 - Electrons
 - 3D-CRT/IMRT
 - Protons
 - Single-dose intraoperative radiotherapy (IORT)
- Multi-catheter interstitial brachytherapy has longest history, but currently data lacking to determine optimal method of delivering APBI.

GEC-ESTRO: Phase III trial

(Strnad et al. 2016)

- Interstitial multi-catheter brachytherapy to partial breast after breast conserving surgery
- 1184 patients treated prospectively with either WBI or APBI
 - Eligibility: Age > 40, negative margins, Tumor ≤3cm or DCIS with Van Nuys ≤ 8, pN0 or pNmi

Modality	N	Median f/u	5-year local recurrence	5-year Cumulative Incidence		5-year DFS
				Regional	Distant	
WBI (50Gy / 25fx + 10Gy boost)	551	6.6 yrs	0.92% (95% CI 0.12-1.73)	0.18%	0.93%	94.45% (95% CI 92.5-96.4)
APBI (32Gy / 8fx or 30.3Gy / 7fx BID)	633	6.6 yrs	1.44% (95% CI 0.51-2.34)	0.48%	0.80%	95.03% (95% CI 93.3-96.7)

GEC-ESTRO: cont'd

- **Toxicity and cosmesis** (Polgár et al. 2017)
 - Skin toxicity at 5 years (% of pts):
 - APBI: Grade 2-3 (12%), 0% G4+
 - WBI: Grade 2-3 (9.7%), 0% G4+
 - Breast pain at 5 years (% of pts):
 - APBI: Grade 2-3 (8.4%), 0% G4+
 - WBI: Grade 2-3 (11.9%), 0% G4+
- Interstitial multi-catheter brachytherapy-based APBI is noninferior to WBRT with regards to outcome and cosmetic outcome

UK IMPORT LOW: Phase III trial

(Coles et al. 2017)

- Comparing APBI to WBI or reduced-dose WBI + simultaneous boost (SIB) IMRT after breast conserving therapy
- 2018 patients treated prospectively, randomized to three groups
 - Eligibility: Age \geq 50, unifocal IDC, grade 1-3, margins \geq 2mm, Tumor \leq 3cm, 0-3 nodes

Modality	N	Median f/u	5-year Cumulative Incidence			5-year Any Breast Cancer Event
			Local	Regional	Distant	
WBI (40Gy / 15fx)	674	72.2 mos	1.1% (95% CI 0.5-2.3)	1.1% (95% CI 0.5-2.3)	1.4% (95% CI 0.7-2.6)	3.7% (95% CI 2.5-5.4)
WBI + SIB (36Gy + 40Gy / 15fx)	673	72.2 mos	0.2% (95% CI 0.02-1.2)	0.2% (95% CI 0.02-1.2)	1.5% (95% CI 0.8-2.8)	3.4% (95% CI 2.2-5.1)
PBI (40Gy / 15fx)	669	72.2 mos	0.5% (95% CI 0.2-1.4)	0.8% (95% CI 0.3-1.8)	1.6% (95% CI 0.8-2.9)	4.0% (95% CI 2.8-5.9)

UK IMPORT LOW: cont'd

- **Change in breast appearance** (Coles et al. 2017)
 - Patients reported at 5 years (% of pts):
 - WBI: 47.7 % (95% CI 41.1-54.8)
 - Reduced WBI + SIB: 36.7: (95% CI 30.6-43.6) $p < 0.05$
 - PBI: 35.1% (95% CI 28.7-43.5) $p < 0.001$
 - Physician reported at 5 years (% of pts):
 - WBI: 27.6 % (95% CI 22.5-33.6)
 - Reduced WBI + SIB: 21.1: (95% CI 17.2-25.7) $p = 0.47$
 - PBI: 20 % (95% CI 15.6-25.4) $p = 0.10$
- EBRT APBI outcomes noninferior to WBI when using IMRT. Low overall adverse events with worse patient-reported cosmesis with APBI

NSABP B39/RTOG 04-13: Phase III trial

(Vicini et al, 2019)

- APBI after breast-conserving surgery for early stage breast cancer
- 4216 patients treated prospectively with WBI or APBI
 - Eligibility: Stage I/II, unifocal, invasive non-lobular, negative margins, Tumor ≤ 3 cm, Level I/II ALND with 0-3 positive nodes without ECE.
 - APBI was either brachytherapy (Mammosite, interstitial) or EBRT

Modality	N	Median f/u	10-year failure	Survival Rate
			Ipsilateral breast	Overall
WBI (50Gy / 25 fx in 5 weeks)	2109	10.2 yrs	3.90%	91.30%
APBI (34Gy / 10fx brachy BID or 38.5Gy / 10fx EBRT BID in 5 days)	2107	10.2 yrs	4.60%	90.60%

RTOG 04-13: Phase III trial (cont'd)

- **Toxicity and cosmesis** (Vicini et al. 2019)
 - Skin toxicity at 10 years (% of pts):
 - APBI: Grade 1 (40%), Grade 2 (44%), Grade 3 (10%), <1% G4+
 - WBI: Grade 1 (31%), Grade 2 (59%), Grade 3 (7%), <1% G4+
- APBI did not meet criteria for equivalence to WBI in controlling for IBTR, but with an absolute difference of 0.7%, study concluded that APBI may be an acceptable alternative for some women

RAPID: Phase III trial

(Whelan et al. 2019)

- EBRT APBI after breast-conserving surgery for early stage breast cancer
- 2135 patients treated prospectively with WBI (hypofrac and conventional) or APBI
 - Eligibility: Age > 40, Tumor ≤ 3cm, IDC or DCIS

Modality	N	Median f/u	8-year ipsilateral breast recurrence
WBI (50Gy / 25fx or 42.5Gy / 16fx)	1065	8.6 yrs	2.8% (95% CI 1.8-3.9)
APBI (38.5Gy / 10fx BID in 5-8 days)	1070	8.6 yrs	3.0% (95% CI 1.9-4.0%)

RAPID: Phase III trial (cont'd)

- **Toxicity and cosmesis** (Whelan et al. 2019)
 - Induration or telangiectasia at 8 years (% of pts)
 - WBI: Grade 2+ (13%)
 - APBI: Grade 2+ (32%), $p < 0.0001$
 - Absolute difference in adverse cosmesis (fair or poor) at 7 years 18% lower (95% CI 12.9-22.3) in APBI group
- APBI is noninferior to WBI in terms of local disease control
- Late skin toxicity and cosmesis worse with APBI using this dosing regimen

Florence Trial - Phase III trial

- Accelerated Partial-Breast Irradiation Compared With Whole-Breast Irradiation for Early Breast Cancer
- 520 patients treated prospectively with WBI or APBI
 - Eligibility: Age > 40, early BC, multifocal, intraductal carcinoma, <5mm surgical margins, tumor ≤ 2.5 cm

Modality	N	Median f/u	10-year failure rates		Survival rates
			Ipsilat. br	Contralat. br	Overall
WBI (50Gy / 25fx)	260	10.7 yrs	2.50%	3.20%	91.90%
APBI (30Gy / 5fx) IMRT	260	10.7 yrs	3.70%	0.80%	91.90%

Florence Trial- Phase III trial (cont'd)

- **Toxicity and cosmesis** (Meattini et al. 2020)
 - Toxicity within 6 months of treatment (% of pts):
 - APBI: Grade 1 (19.1%), Grade 2 (2%), No Grade 3
 - WBI: Grade 1 (28.8%), Grade 2 (31.2%), Grade 3 (6.5%)
 - Physician rated cosmesis at 10 years (% of pts):
 - APBI: Excellent (94.7%), Good (5.3%), Fair (0%), Poor (0%)
 - WBI: Excellent (72.7%), Good (25.4%), Fair (1.9%), Poor (0%)
- IBRT incidence was not significantly different between APBI and WBI
- Treatment related toxicity and cosmesis outcomes significant favor APBI for low-risk early breast cancer

Intraoperative Radiotherapy (IORT)

- TARGIT-A: randomized phase III (Vaidya et al. 2020)
 - 2298 patients: PBI IORT (20Gy/ 1fx) or WBI (45-56Gy)
 - Immediate IORT 5-year local recurrence: 2.11% vs. 0.95% (not inferior)
 - Delayed IORT 5-year local recurrence: 3.96% vs. 1.05% (inferior)
 - 20% of IORT patients needed WBI due to adverse pathology
- ELIOT: randomized phase III (Veronesi et al. 2013)
 - 1305 patients: PBI IORT (21Gy/ 1fx) or WBI (50Gy / 25fx + 10Gy)
 - 15-year Ipsilateral Breast Tumor Recurrence– 13% vs. 2.4% (inferior)
 - 40% of recurrences within radiation field
 - Not all of patients would satisfy ASTRO APBI appropriateness
- IORT APBI remains controversial with faster treatment and lower costs, but concerns for patient selection and effectiveness

NCCN v 3.2022 Guidelines

Accelerated Partial Breast Irradiation (APBI)

- Studies of APBI suggest that rates of local control in selected low-risk patients with early-stage breast cancer are comparable to those treated with standard WBRT. However, compared to standard WBRT, several studies document an inferior cosmetic outcome with external beam delivery methods of APBI. Follow-up is limited and studies are ongoing.
 - Patients are encouraged to participate in clinical trials.
 - The NCCN Panel accepts the updated 2016 version of the ASTRO APBI guideline consensus statement, which now defines patients age ≥ 50 years to be considered "suitable" for APBI if:
 - ◊ Invasive ductal carcinoma measuring ≤ 2 cm (pT1 disease) with negative margin widths of ≥ 2 mm, no LVI, ER-positive, and BRCA negative; or
 - ◊ Low/intermediate nuclear grade, screening-detected DCIS measuring size ≤ 2.5 cm with negative margin widths of ≥ 3 mm.
- RT dosing

Regimen	Method	Reference
30 Gy/5 fractions QOD (preferred)	External beam RT (EBRT) ^e	Livi L, Meattini I, Marrazzo L, et al. Accelerated partial breast irradiation using intensity-modulated radiotherapy versus whole breast irradiation: 5-year survival analysis of a phase 3 randomised controlled trial. <i>Eur J Cancer</i> 2015;51:451-463. Meattini I, Marrazzo L, Saieva C, et al. Accelerated partial-breast irradiation compared with whole-breast irradiation for early breast cancer: Long-term results of the randomized phase III APBI-IMRT-Florence Trial. <i>J Clin Oncol</i> 2020;38:4175-4183.
40 Gy/15 fractions	EBRT	Coles CE, Griffin CL, Kirby AM, et al. Partial-breast radiotherapy after breast conservation surgery for patients with early breast cancer (UK IMPORT LOW trial): 5-year results from a multicentre, randomised, controlled, phase 3, non-inferiority trial. <i>Lancet</i> 2017;390:1048-1060.
34 Gy/10 fractions BID	Balloon/ Interstitial	Vicini FA, Cecchini RS, White JR, et al. Long-term primary results of accelerated partial breast irradiation after BCS for early-stage breast cancer: a randomised, phase 3, equivalence trial. <i>Lancet</i> 2019;394:2155-2164.
38.5 Gy/10 fractions BID	EBRT	Whelan TJ, Julian JA, Berrang TS, et al. External beam accelerated partial breast irradiation versus whole breast irradiation after breast conserving surgery in women with ductal carcinoma in situ and node-negative breast cancer (RAPID): a randomised controlled trial. <i>Lancet</i> 2019;394:2165-2172.

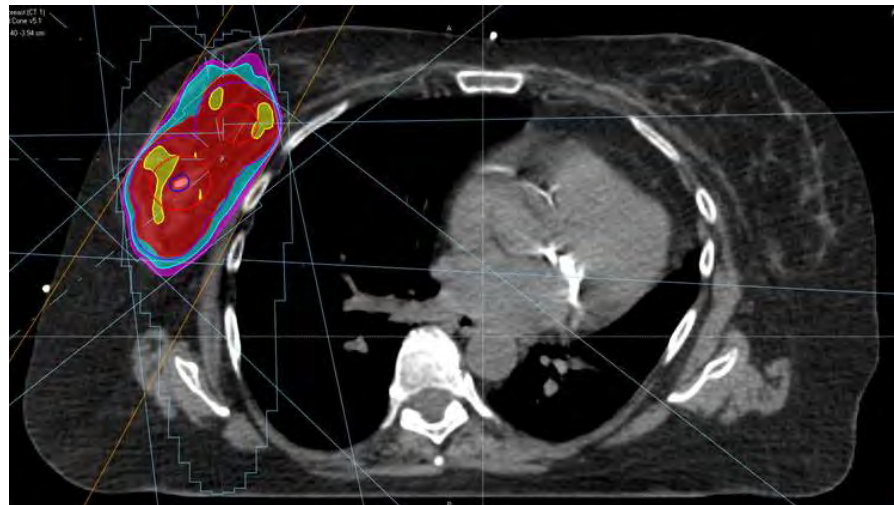
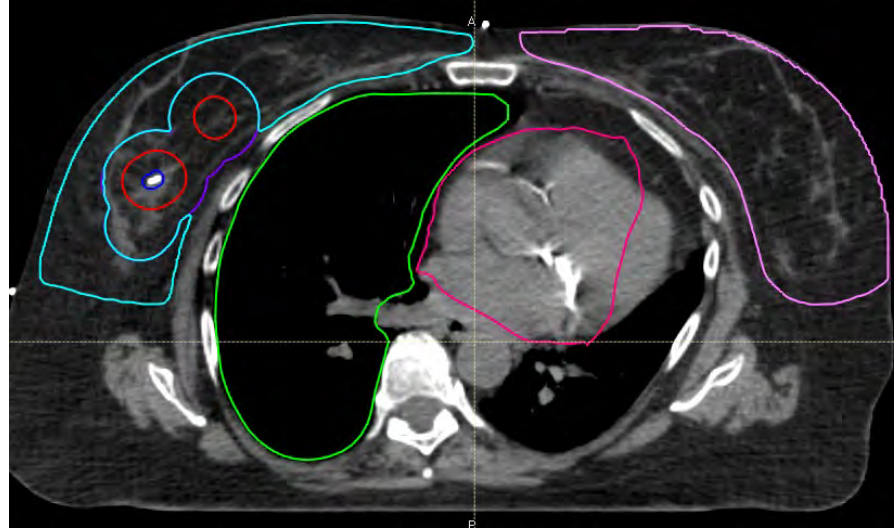
Treatment

- Our patient underwent lumpectomy
 - Invasive ductal carcinoma measuring 3mm
 - Associated DCIS
 - Surgical resection margins widely negative (>10mm for all margins)
 - ER100, PR>90, HER2 1+, H2n- by IHC
 - SLNBx reviewed intraoperatively 0/2 LNs positive for disease

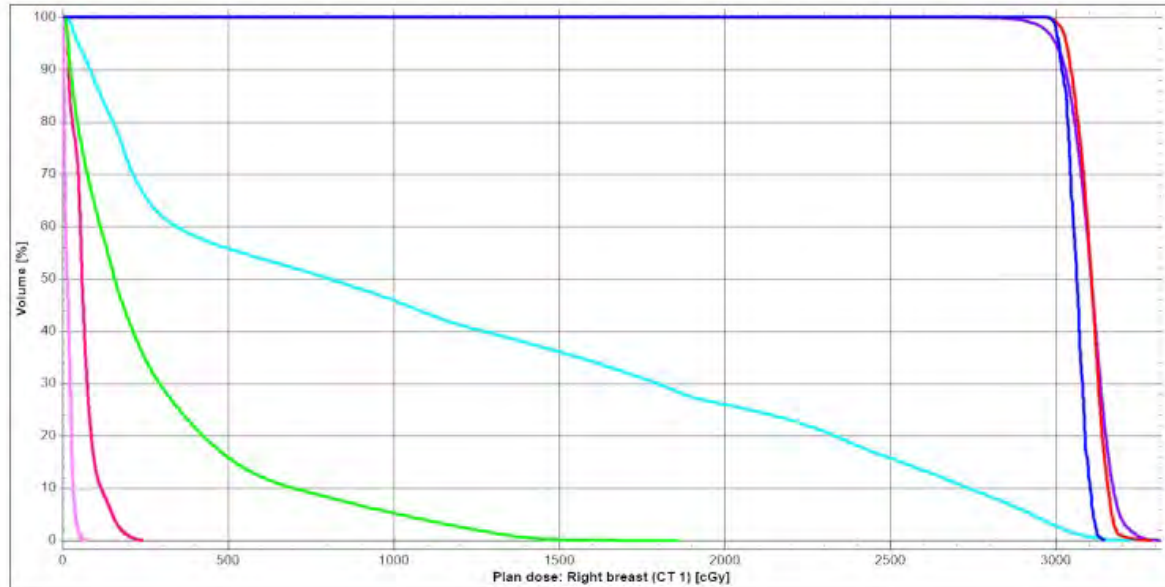
Treatment Planning

- Clinical target volume was drawn with a uniform 1 cm 3-D margin around surgical clips
- Second uniform 3-D 1 cm margin was added to obtain planning target volume
- Six 6MV step and shoot IMRT coplanar fields were used
- Patient was positioned supine with wing board with a vacloc and arms up
- Radiation was aligned to surgical clips daily
- 30Gy in 5 fractions every other day
- Clips were reviewed for evidence of migration but none
- Per the Italian Trial protocol that CTV limited to 3mm from skin, PTV was allowed to extend 4 mm into ipsilateral lung and limited 3 mm from the skin

Treatment Planning



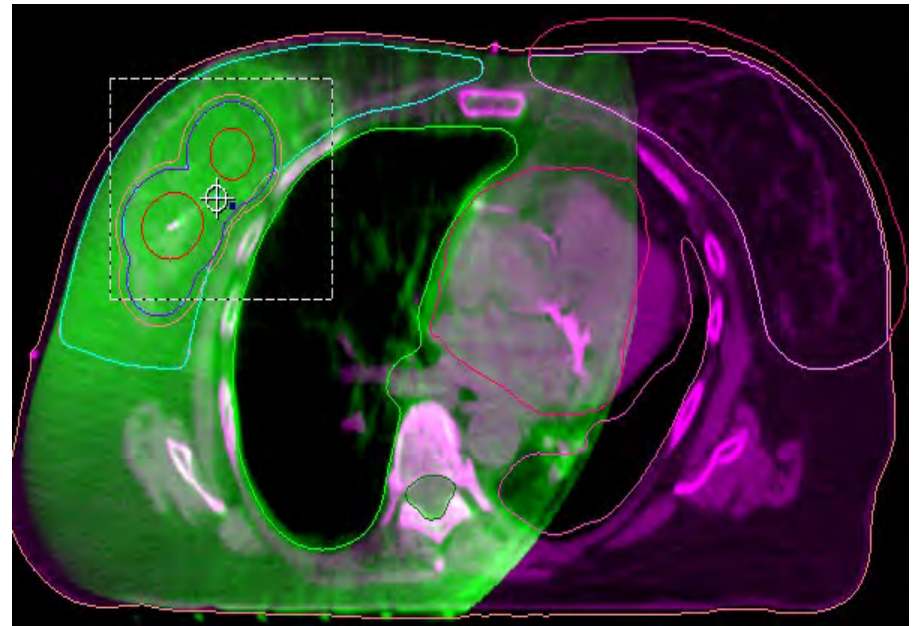
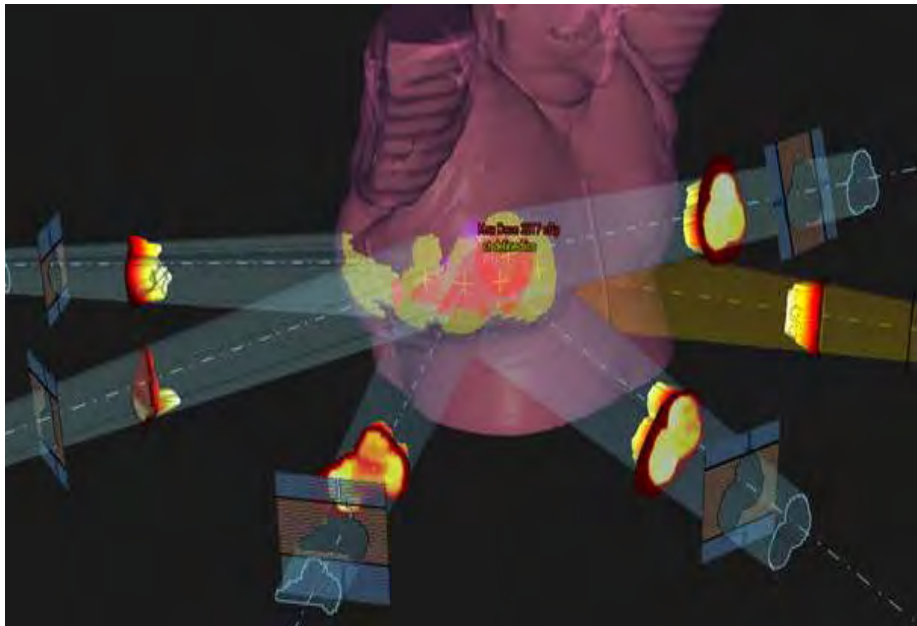
Treatment Planning



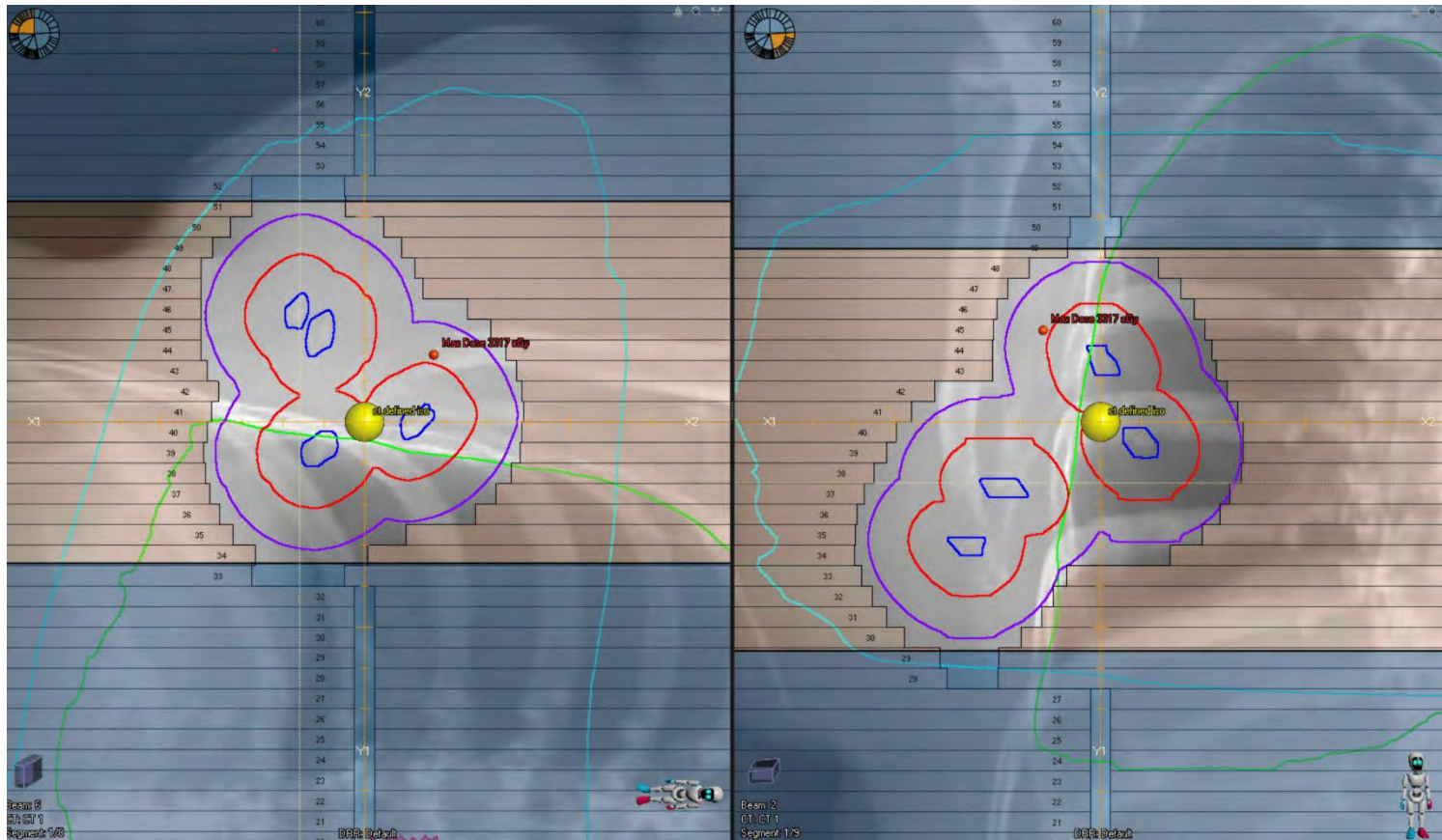
Dose	ROI/POI	Clinical goal	Value	Result
Plan dose: Right breas...	■ BREAST_L contract	At most 100 cGy dose at 0.00 cm ³ volume	78 cGy	✓
Plan dose: Right breas...	■ BREAST_L contract	At most 200 cGy dose at 0.00 cm ³ volume	78 cGy	✓
Plan dose: Right breas...	▲ CTV	At least 90.00 % volume at 3000 cGy dose	99.22 %	✓
Plan dose: Right breas...	▲ CTV	At least 95.00 % volume at 2850 cGy dose	100.00 %	✓
Plan dose: Right breas...	■ Lung (Right)	At most 10.00 % volume at 1000 cGy dose	5.21 %	✓
Plan dose: Right breas...	▲ PTV	At least 3000 cGy dose at 95.00 % volume	3000 cGy	✓
Plan dose: Right breas...	▲ PTV	At most 2.00 % volume at 3237 cGy dose	1.33 %	✓
Plan dose: Right breas...	▲ Uninvolved Breast	At most 50.00 % volume at 1500 cGy dose	36.05 %	✓

Treatment Set Up

with daily CBCT before each fraction



Portal View



References

- Shah C, Vicini F, Wazer DE, Arthur D, Patel RR. The American Brachytherapy Society consensus statement for accelerated partial breast irradiation. *Brachytherapy*. 2013;12(4):267-277.
- Correa C, Harris EE, Leonardi MC, et al. Accelerated Partial Breast Irradiation: Executive summary for the update of an ASTRO Evidence-Based Consensus Statement. *Pract Radiat Oncol*. 2017;7(2):73-79. doi:10.1016/j.prro.2016.09.007
- Strnad V, Ott OJ, Hildebrandt G, et al. 5-year results of accelerated partial breast irradiation using sole interstitial multicatheter brachytherapy versus whole-breast irradiation with boost after breast-conserving surgery for low-risk invasive and in-situ carcinoma of the female breast: a randomised, phase 3, non-inferiority trial. *Lancet*. 2016;387(10015):229-238.
- Polgár C, Ott OJ, Hildebrandt G, et al. Late side-effects and cosmetic results of accelerated partial breast irradiation with interstitial brachytherapy versus whole-breast irradiation after breast-conserving surgery for low-risk invasive and in-situ carcinoma of the female breast: 5-year results of a randomised, controlled, phase 3 trial. *Lancet Oncol*. 2017;18(2):259-268.
- Coles CE, Griffin CL, Kirby AM, et al. Partial-breast radiotherapy after breast conservation surgery for patients with early breast cancer (UK IMPORT LOW trial): 5-year results from a multicentre, randomised, controlled, phase 3, non-inferiority trial. *Lancet*. 2017;390(10099):1048-1060.
- Vicini FA, Cecchini RS, White JR, et al. Long-term primary results of accelerated partial breast irradiation after breast-conserving surgery for early-stage breast cancer: a randomised, phase 3, equivalence trial. *Lancet*. 2019;394(10215):2155-2164.
- Whelan TJ, Julian JA, Berrang TS, et al. External beam accelerated partial breast irradiation versus whole breast irradiation after breast conserving surgery in women with ductal carcinoma in situ and node-negative breast cancer (RAPID): a randomised controlled trial. *Lancet*. 2019;394(10215):2165-2172.
- Meattini I, Marrazzo L, Saieva C, et al. Accelerated Partial-Breast Irradiation Compared With Whole-Breast Irradiation for Early Breast Cancer: Long-Term Results of the Randomized Phase III APBI-IMRT-Florence Trial. *J Clin Oncol*. 2020;38(35):4175-4183.
- Veronesi U, Orecchia R, Maisonneuve P, et al. Intraoperative radiotherapy versus external radiotherapy for early breast cancer (ELIOT): a randomised controlled equivalence trial. *Lancet Oncol*. 2013;14(13):1269-1277.
- Vaidya JS, Bulsara M, Baum M, et al. Long term survival and local control outcomes from single dose targeted intraoperative radiotherapy during lumpectomy (TARGIT-IORT) for early breast cancer: TARGIT-A randomised clinical trial. *BMJ*. 2020;370:m2836.

Please provide feedback regarding this case or other ARROcases to arrocases@gmail.com