

ARROCase: Early Stage Favorable Classic Hodgkin Lymphoma

Haoming Qiu, MD, PGY-4 Resident
Faculty Mentor – Louis S. Constine, MD, FASTRO
University of Rochester Medical Center
January 2015

Case Presentation: History

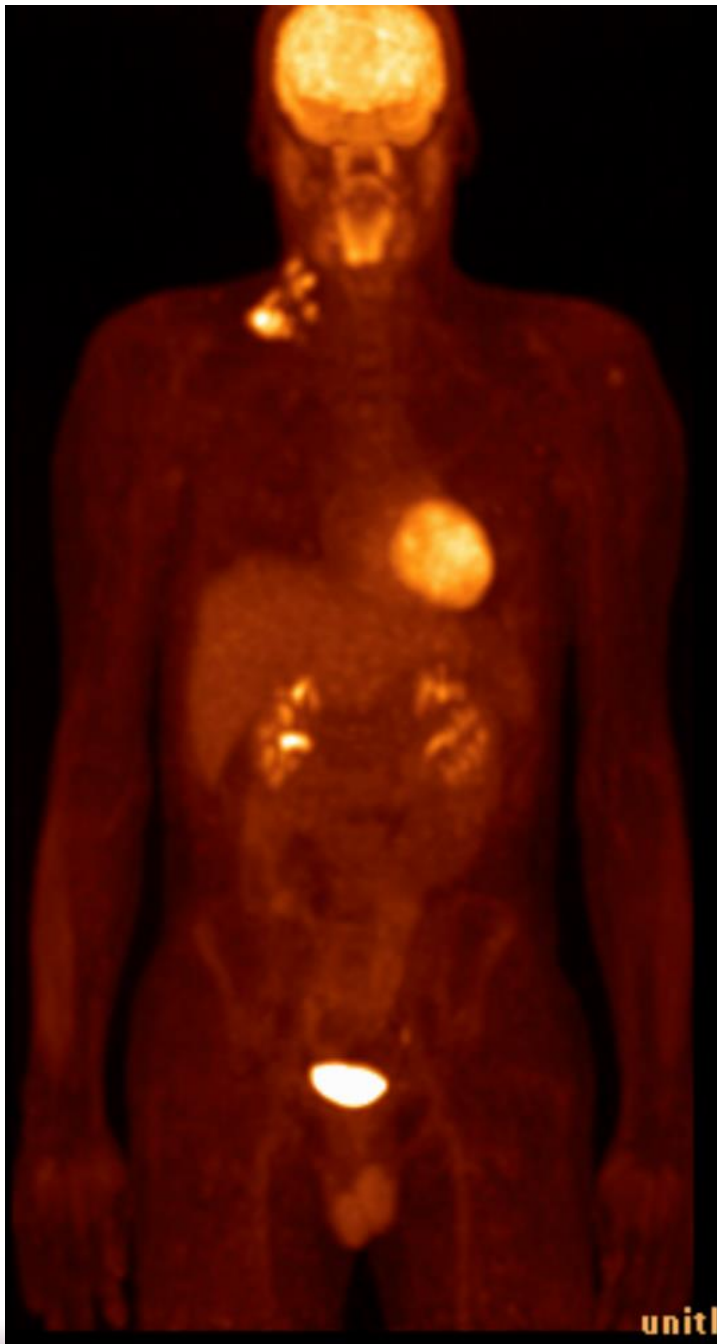
- 29 yo male previously healthy who noted intermittent neck node enlargement since 2011
- In late 2013, the nodal enlargement became more prominent and persistent. He also started to experience night sweats but denied any fevers or weight loss.
- MRI of the neck was completed showing right neck adenopathy
- In Dec 2013, an U/S guided FNA of a right neck node showed large atypical mononuclear cells present in a background of polymorphous lymphocytes.
- Labs were significant for a normal CBC and CMP, LDH with an ESR of 5.
- In Jan 2014, a core biopsy was completed

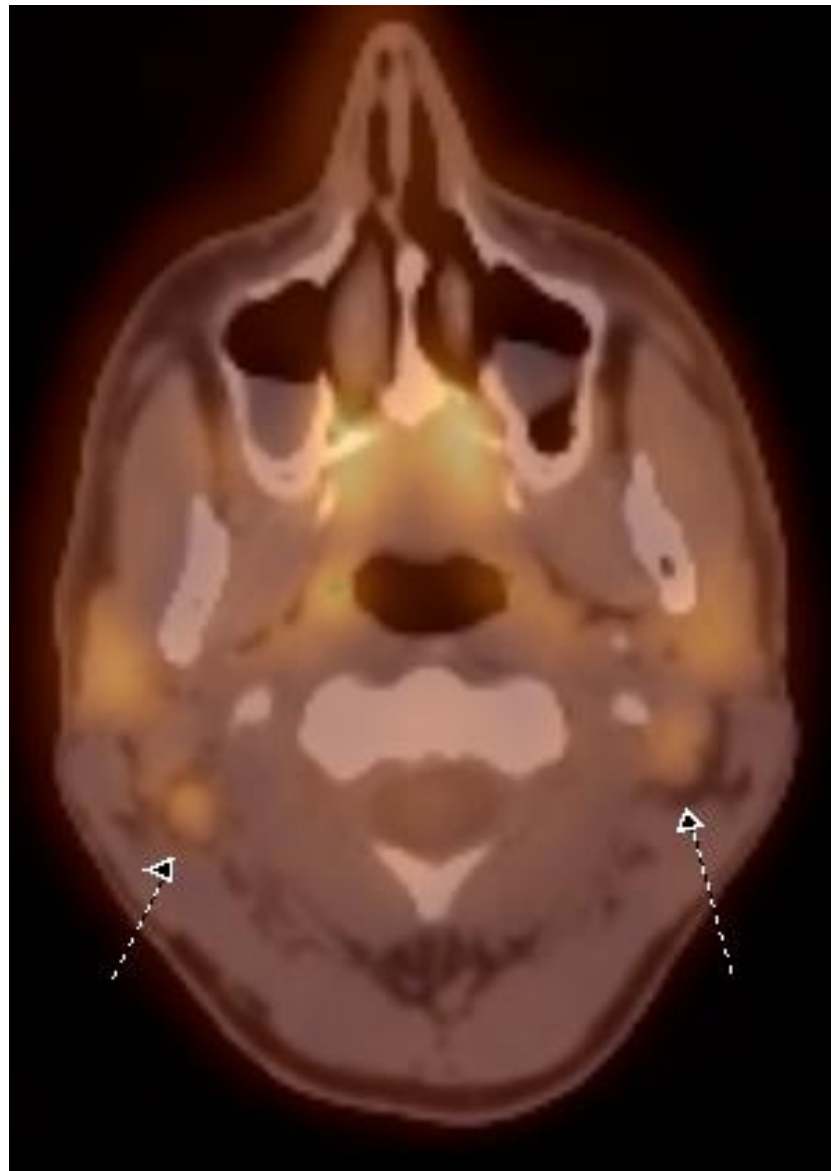
Case Presentation: Pathology

- Pathology revealed “lymph node architecture that was entirely effaced by numerous lymphocytes and few histiocytes; scattered among these cells are several binucleated and multinucleated Reed-Sternberg (RS) cells with prominent inclusion-like nucleoli. Scattered mummified RS cells are also present.”
- Immunohistochemical stains show the RS cells stain strongly positive for CD30, PAX5, and mostly negative for CD15. A subset of RS cells are positive for CD20
- This was consistent with classical Hodgkin Lymphoma
- The abundant mixed lymphocytic background and the positive EBV-staining are most consistent with mixed cellularity subtype of classical Hodgkin Lymphoma.

PET/CT was completed showing:

- Hypermetabolic predominantly right neck lymphadenopathy involving level II, level IV and level V nodes (SUV up to 12.8), consistent with biopsy-proven Hodgkin's lymphoma. There is also a tiny hypermetabolic left level II node.
- No hypermetabolic lymphadenopathy is identified in the chest, abdomen or pelvis. No focal hypermetabolism within the liver/spleen or the visible bone marrow.
- Bilateral subpleural patchy nodular consolidation of low-grade uptake predominantly in the lower lobes. There is also a mildly hypermetabolic left upper lobe pulmonary nodule measuring approximately 1.0 cm





Bilateral Level 2 adenopathy.

Case Presentation

- Due to the presence of lung nodules, patient underwent a course of antibiotic therapy for presumed infection
- On repeat imaging the lung nodules persisted and the patient underwent VATS thoracotomy which revealed the lesions to be organizing pneumonia
 - Teaching point- the presence of lung nodules does not automatically mean stage IV disease, especially if disease burden is otherwise low. Histological confirmation should be obtained to guide treatment decision.

Staging

- Stage IIB
 - Due to bilateral cervical adenopathy based on PET and presence of night sweats
- Some investigators believe that night sweats alone is not as significant a risk factor as weight loss and fevers

Ann Arbor Staging System for Lymphoma

- Stage 1- Involvement of a single lymphatic site (i.e., nodal region, Waldeyer's ring, thymus, or spleen) (I); or localized involvement of a single extralymphatic organ or site in the absence of any lymph node involvement
- Stage II- Involvement of two or more lymph node regions on the same side of the diaphragm (II); or localized involvement of a single extralymphatic organ or site in association with regional lymph node involvement with or without involvement of other lymph node regions on the same side of the diaphragm
- Stage III- Involvement of lymph node regions on both sides of the diaphragm , which also may be accompanied by extralymphatic extension in association with adjacent lymph node involvement or by involvement of the spleen or both
- Stage IV- Diffuse or disseminated involvement of one or more extralymphatic organs, with or without associated lymph node involvement; or isolated extralymphatic organ involvement in the absence of adjacent regional lymph node involvement, but in conjunction with disease in distant site(s). Stage IV includes any involvement of the liver or bone marrow, lungs (other than by direct extension from another site), or cerebrospinal fluid

- **Additional Designations**
- E- Extralymphatic Invasion
- S- Splenic involvement
- X- Bulky (>1/3 mediastinal width or >10cm)
- B- "B symptoms" including:
 - Unintentional Loss of more than 10% of body weight over the previous 6 months
 - Unexplained fever of at least 101.5° F
 - Drenching night sweats

Background- Epidemiology

- In 2014, in the United States Hodgkin Lymphoma (HL)
 - Incidence - 9,190
 - Mortality- 1,180
- Bi-modal distribution with higher incidence from 25-30 years of age and from 75-80 years.
- Median age is 26
- Slight male predominance of 1.2: 1
- Possible association with EBV infection particularly in Mixed-Cellularity Type (as in our patient)

1. American Cancer Society: Cancer Facts and Figures 2014. Atlanta, Ga: American Cancer Society, 2014. Available online Exit Disclaimer. Last accessed November 24, 2014.
2. Hoppe, R. "Hodgkin's Lymphoma" in Perez and Brady 6th Edition. Chapter 77.

Clinical Presentation

- Most commonly, patients present with painless adenopathy
- Some report “B” symptoms of fevers, drenching night sweats or weight loss and other systemic symptoms like pruritus, fatigue and alcohol induced pain.
- Disease usually spreads to contiguous nodal regions
- Organ involvement can be via direct extension or hematogenous spread

Pathologic Classification

- Characteristic feature is Reed-Sternberg cell which is typically binucleate with a prominent centrally located nucleolus, well-demarcated nuclear membrane, and eosinophilic cytoplasm with a perinuclear halo. It is present in <1% of of a lymph node involved by HL.
- In most instances, the RS cells stain positively with CD30 and PAX5 (as our patient did) with variable expression of CD15 and CD20.
- The WHO defines 5 subtypes of HL.
- 4 subtypes of classic HL:
 - nodular sclerosis- most common, good prognosis
 - mixed cellularity- presents with more adv. disease, less favorable
 - lymphocyte-rich- rare, good prognosis
 - lymphocyte-depleted- Very rare, worst prognosis
- 1 type of non-classic HL - nodular lymphocyte-predominant Hodgkin lymphoma. (Positive for CD20, CD45, CD79a, and PAX5 and negative for CD15 and CD30).

Diagnostic Workup

- H&P
 - With attention to B-symptoms (unexplained fever, drenching night sweats, weight loss) alcohol intolerance, pruritus, fatigue and performance status
 - Careful exam of the lymph nodes including cervical, supraclavicular, axilla, inguinal. Abdominal exam for hepatosplenomegaly
- Lab Tests- CBC, BMP, LFTs, albumin, LDH, ESR, pregnancy test in women of child bearing age
- Imaging- CXR (esp to evaluate any mediastinal adenopathy), CT of C/A/P, PET/CT
- Pathology- Excisional biopsy usually needed for nodal architecture, consider bone marrow bx if advanced disease or significant B symptoms (overall incidence ~5%)
- Bone marrow biopsy in stage IB, IIB and stage III-IV

Risk Stratification

- There are many different schemes for risk stratification including GHSG, EORTC, ECOG/NCIC, Stanford and NCCN (see appendix A)
- The German Hodgkin Study group (GHSG) classifies Hodgkin Lymphoma into early stage favorable and unfavorable with risk factors of:
 - a) maximum width of mass/maximum intrathoracic diameter (MMR) > 0.33
 - b) Extranodal disease
 - c) ESR ≥ 50 without B-symptoms or ≥ 30 with B-symptoms
 - d) ≥ 3 nodal areas
- Early stage Favorable- Stage I-II without any risk factors
- Early stage Unfavorable- Stage I or IIA with ≥ 1 risk factor or, Stage IIB with only **c** or **d** but not **a** or **b**
- This patient was considered GHSG early stage favorable given he had no risk factors and was stage II.
- He was treated according to the GHSG HD10 study

Treatment

- Historically, radiation therapy (RT) alone has been used to treat early stage favorable HL.
- Chemotherapy using MOPP then ABVD was also found to be effective. (1)
- The EORTC H8-F trial showed that combined modality therapy (CMT) of (Involved field RT+ Chemotherapy) results in improved event free and overall survival compared with RT alone. (2)
- The GHSG HD10 trial showed that for patients with early stage favorable HL, there was no difference in 5 year treatment failure or overall survival between 4 cycles of ABVD vs. 2 cycles ABVD and no difference between 30 Gy of IFRT and 20 Gy of IFRT. (3)
 - The 5 yr freedom from treatment failure for the entire cohort was 92% and the 5 yr OS was 96.8%.

1. DeVita, Ann Intern Med, 1980 and Canellos, NEJM, 1992

2. Fermé C, et al.: Chemotherapy plus involved-field radiation in early-stage Hodgkin's disease. NEJM 2007

3 Reduced treatment intensity in patients with early-stage Hodgkin's lymphoma. NEJM 2010.

Treatment

- The classic RT field for treatment of HL is involved field RT (IFRT) which is defined based on bony landmarks (1)
- Newer recommendations (2) introduced the concept of involved site RT (ISRT) and involved node (INRT) for treatment of HL.
- ISRT targets radiation only to areas of gross disease (+ margin) on pre-chemotherapy imaging.
- ISRT reduces the RT volume compared with IFRT
- INRT targets only involved node with smaller margins than ISRT but requires pre-chemotherapy PET/CT in the RT treatment position for precise image fusion

1. Yahalom et al. The involved field is back: issues in delineating the radiation field in Hodgkin's disease. Ann Oncology. 2002.

2. Specht et al. Modern Radiation Therapy for Hodgkin Lymphoma: Field and Dose Guidelines from ILROG. IJROBP 2013.

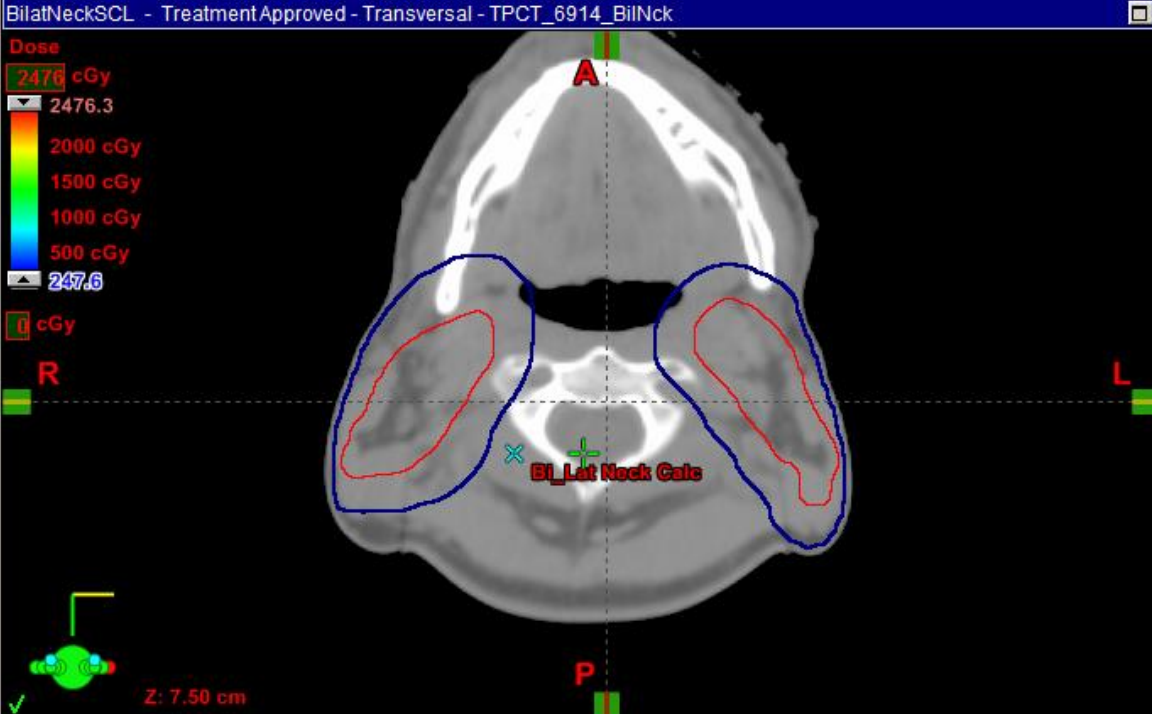
How would you treat this patient?

- Patient staged as having Stage IIB Early Stage Favorable HL – Mixed cellularity subtype.
- After discussion at tumor board, it was recommended he receive 2 cycles of ABVD followed by 20 Gy of IFRT to the bilateral cervical lymph nodes according to the GHSG HD10 study
- HD10 was chosen due to its long term follow up, excellent efficacy and relatively low intensity of treatment
- IFRT was used because it was given in the HD10 protocol (although ISRT is a reasonable alternative as well)

Treatment course

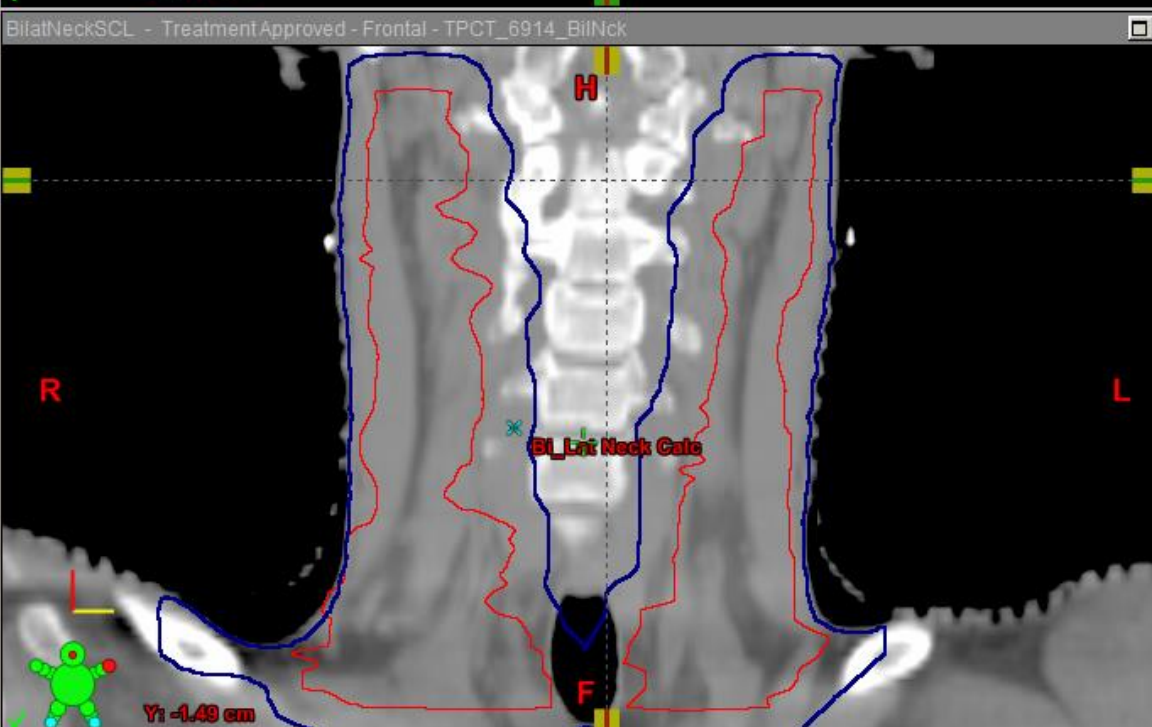- He underwent sperm banking prior to chemotherapy
- He tolerate 2 cycles of ABVD with minor toxicities.
- Re-Staging CT scan showed partial anatomic response to chemotherapy

- Simulation
 - Patient underwent CT simulation with aquaplast head and neck mask
 - Pre-Chemotherapy PET/CT was fused to planning CT to aide in target delineation
 - PET/CT confirmed complete resolution of PET avidity



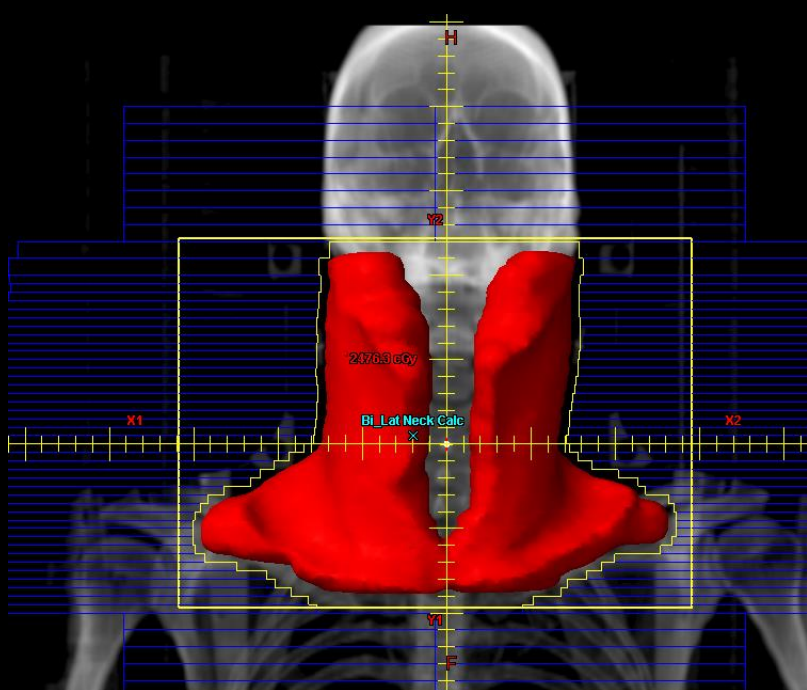
• Volumes

- CTV covered the bilateral cervical lymph nodes levels II-V (including supraclavicular nodes)
- 1cm expansion in all direction for PTV
- PTV was then trimmed to inside body

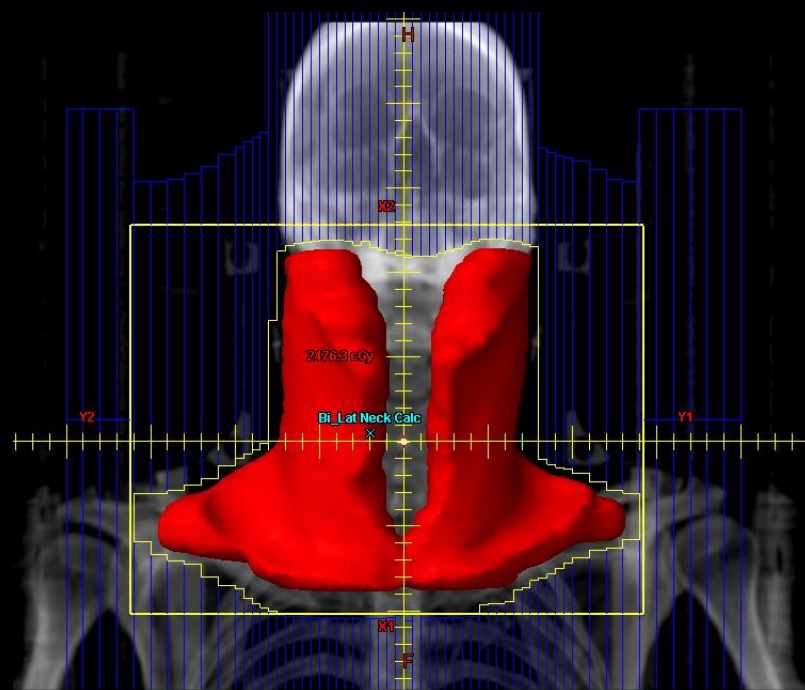


• Dose/fields

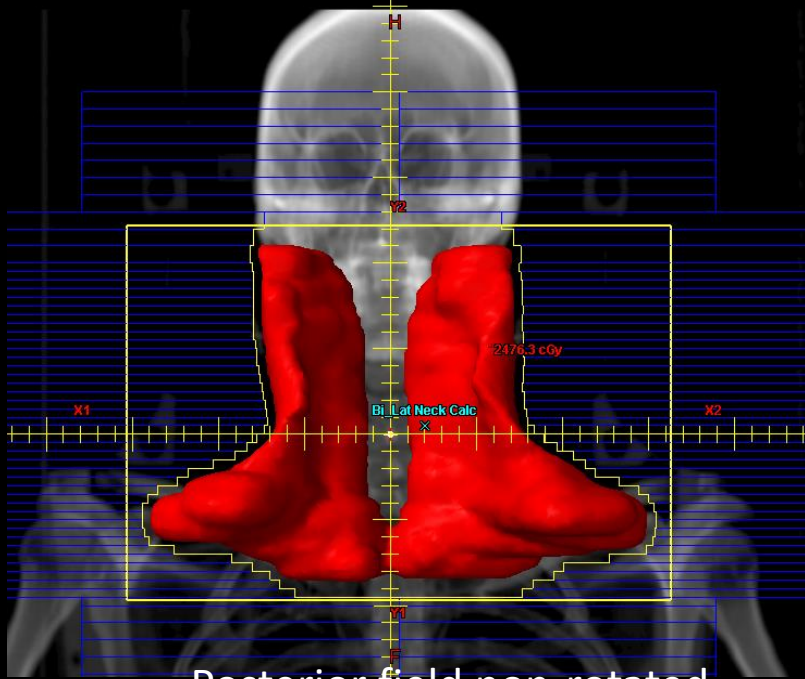
- 20Gy in 10fx
- AP/PA fields
- Mixed photons of 6 MV and 16MV
- PA midline spinal cord block



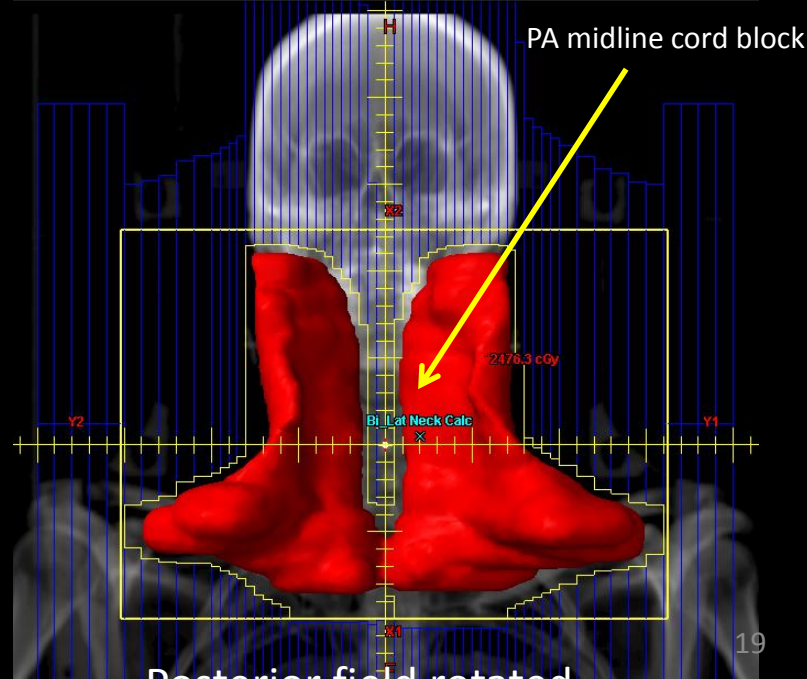
Anterior field non-rotated



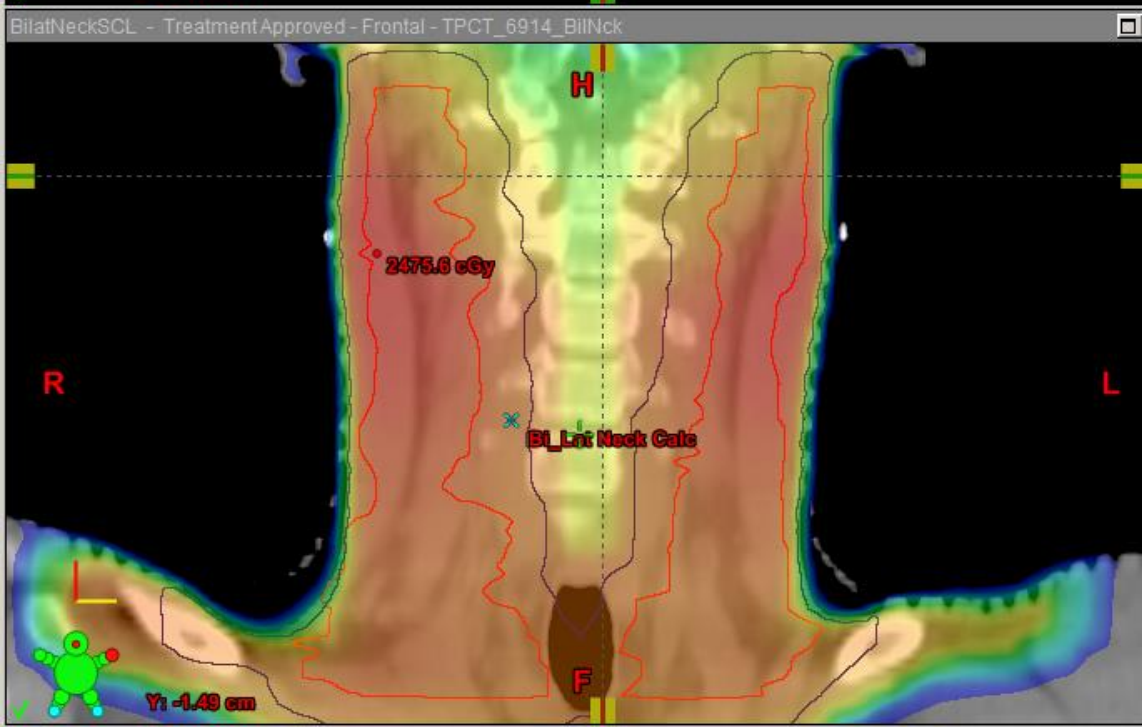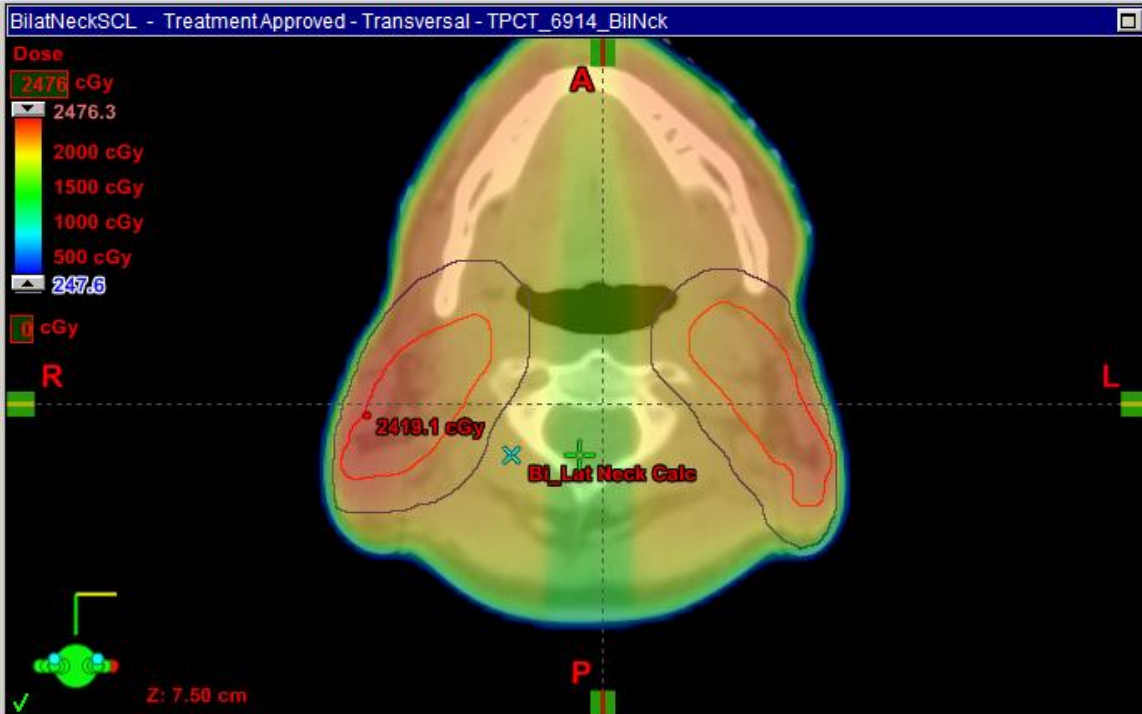
Anterior field rotated



Posterior field non-rotated



Posterior field rotated



- Plan review:
- 95% of PTV was receiving Rx dose of 20 Gy
- Mean dose
 - Left parotid- 20.2 Gy
 - Right parotid- 20.1 Gy
- Max dose
 - Spinal canal- 14.3

Treatment course

- Patient completed RT as prescribed
- Side effects:
 - Grade 2-3 oral mucositis for which he was prescribed pain medications and mouth wash
 - Thrush for which he was prescribed Nystatin
- PET/CT in Oct 2014, approx 3 month after treatment showed complete anatomic and metabolic resolution of disease. No evidence of previous pulmonary nodules.

Follow up per NCCN (ver 2.2014)

- H&P q 3-6 month for 2 years then every 6-12 month until year 3 then annually
- CXR or CT every 6-12 month for 2 years then optional CXR
- CT Abdomen Pelvis every 6-12 month for 2 years
- Newer recommendations in progress may further reduce the extent and frequency of post treatment scans to reduce radiation exposure.

Follow up

- Patient received a total of:
 - 2 cycles ABVD total chemo: (Adriamycin 100mg/m², Bleomycin 40 units/m², Vinblastine 24 mg/m², DTIC 1500 mg/m²)
 - Involved field RT of 20 Gy to the bilateral neck
 - Long term side effects included xerostomia that was managed symptomatically
- How should we screen for and manage other potential late effects?

Screening for late effects

- Main late effects are cardiac and second malignancy.
- Survivorship recommendations per NCCN ver. 2.2014
 - Annual check of blood pressure, lipid profile, aggressive mgmt of cardiac risk factors
 - Consider stress/test ECHO (especially if >30 Gy to heart and/or 300mg/m² of doxorubicin)
 - Thyroid function tests if RT to neck
 - Continued chest imaging for patients with risk factors for lung cancer
 - For Women, Breast imaging 8-10 years after RT. MRI in addition to mammogram
- Treatment summary and transfer care to PCP and/or referral to survivorship clinic
- Additional considerations
 - If XRT to the neck- also consider thyroid ultrasound at 8-10 years and also carotid ultrasound at 10 years.
 - If any abdominal XRT- Colonoscopy after 15 years

Appendix A- Risk Stratification Systems

- **GHSG:**
 - Risk factors
 - a) maximum width of mass/maximum intrathoracic diameter (MMR) > 0.33
 - b) Extranodal disease
 - c) ESR \geq 50 without B-symptoms or \geq 30 with B-symptoms
 - d) \geq 3 nodal areas
 - Favorable- Stage I-II without any risk factors
 - Unfavorable- Stage I or IIA with \geq 1 risk factor or, Stage IIB with only **c** or **d** but not **a** or **b**

EORTC

- Risk factors
 - a) Large mediastinal mass MMR > 0.35
 - b) Age \geq 50 years
 - c) ESR \geq 50 without B-symptoms or \geq 30 with B-symptoms
 - d) \geq 4 nodal areas
- Favorable- Stage I-II supradiaphragmatic without any risk factors
- Unfavorable- Stage I-II supradiaphragmatic with 1 or more risk factor

Appendix A- Risk Stratification Systems

- **NCIC and ECOG:**
 - Risk factors
 - a) Histology other than LP/NS
 - b) Age \geq 40 years
 - c) ESR \geq 50
 - d) \geq 4 nodal areas
 - Favorable- Stage I-II without any risk factors
 - Unfavorable- Stage I-II with 1 or more risk factors

Stanford

- Risk factors
 - a) B-symptoms
 - b) Large mediastinal mass
- Favorable- Stage I-II without any risk factors
- Unfavorable- Stage I-II with 1 or more risk factor

Appendix A- Risk Stratification Systems

- **NCCN**
 - Risk factors
 - a. ESR>50 or any B sx's
 - b. MMR>0.33
 - c. >3 nodal sites
 - d. Bulky disease >10cm
 - Favorable- Stage I-II without any risk factors
 - Unfavorable- Stage I-II with 1 or more risk factor